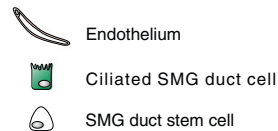
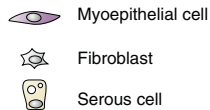
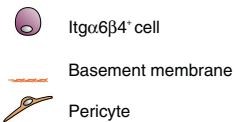
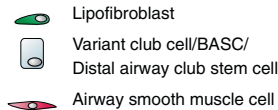
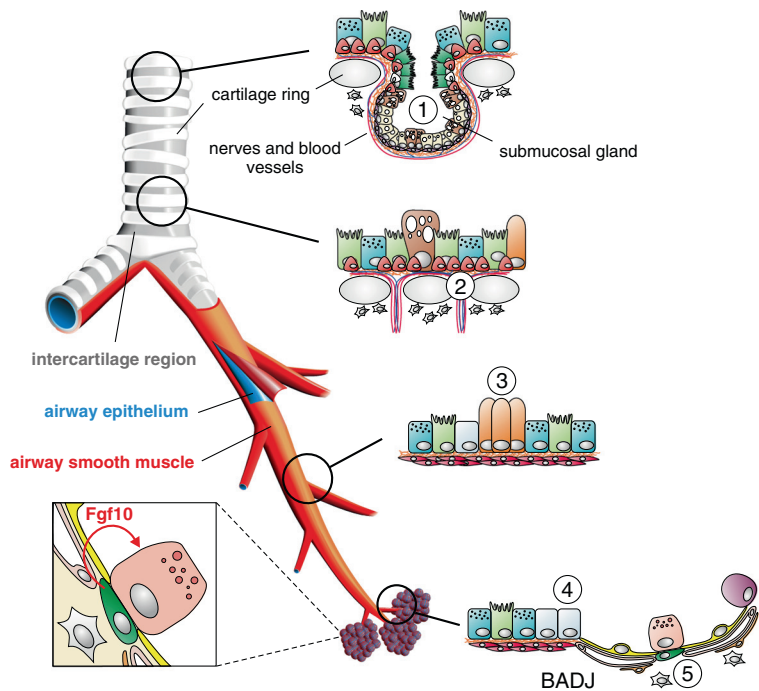


A.

Trachea and main stem bronchi (cartilaginous airways)

Intralobar airways

Alveoli



B.

Normal homeostasis

