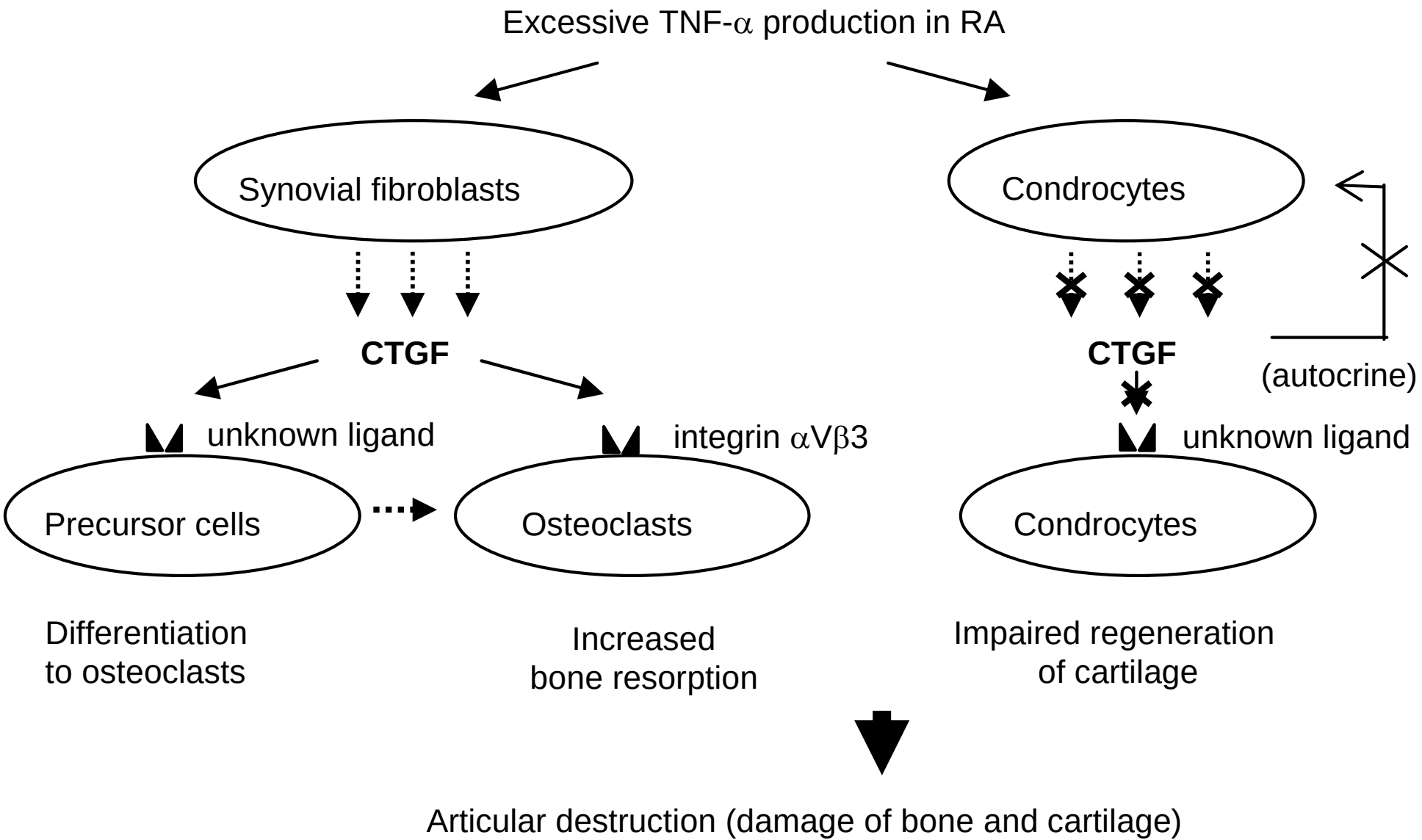
Excessive TNF-α production in RA
Synovial fibroblasts
Condrocytes
CTGF
CTGF
(autocrine)
unknown ligand
integrin αVβ3
unknown ligand
Precursor cells
Osteoclasts
Condrocytes
Differentiation
to osteoclasts
Increased
bone resorption
Impaired regeneration
of cartilage
Articular destruction (damage of bone and cartilage)