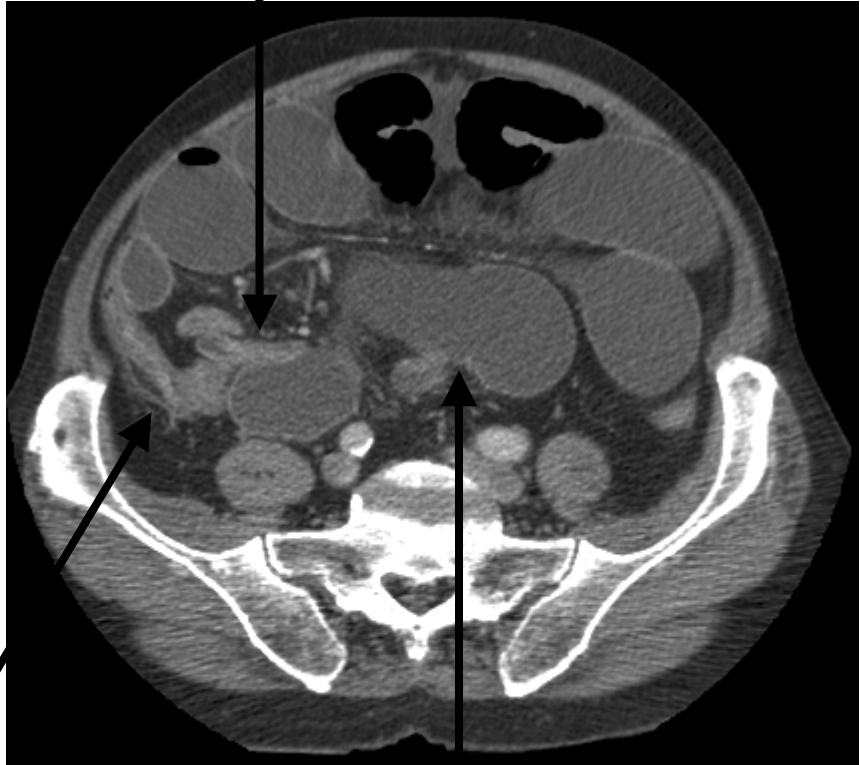


**Meckel's diverticulum ?**



**Collapsed large bowel**

**Small bowel dilatation**