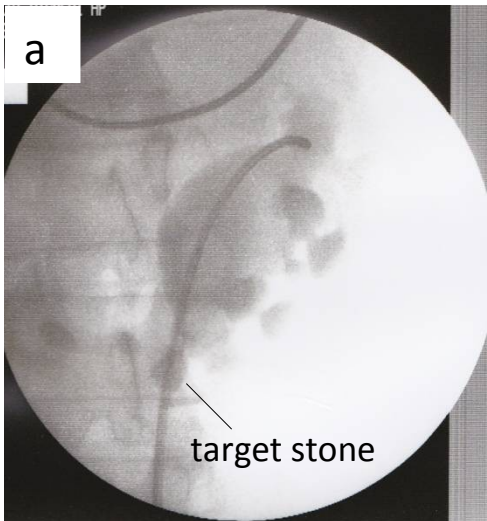


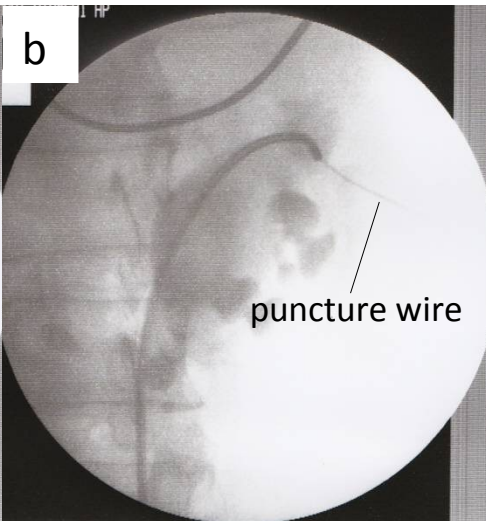
a

target stone

Fluoroscopic image (a) showing a target stone in the kidney. The stone is a bright, irregularly shaped mass located in the lower pole of the kidney. A thin, dark line points from the label 'target stone' to the stone. The surrounding renal anatomy, including the collecting system and the renal pelvis, is visible in a grayscale, semi-transparent style.

b

puncture wire

Fluoroscopic image (b) showing a puncture wire in the kidney. The wire is a thin, dark line that has been inserted into the kidney, likely for percutaneous nephrolithotomy. A thin, dark line points from the label 'puncture wire' to the wire. The surrounding renal anatomy is visible in a grayscale, semi-transparent style.