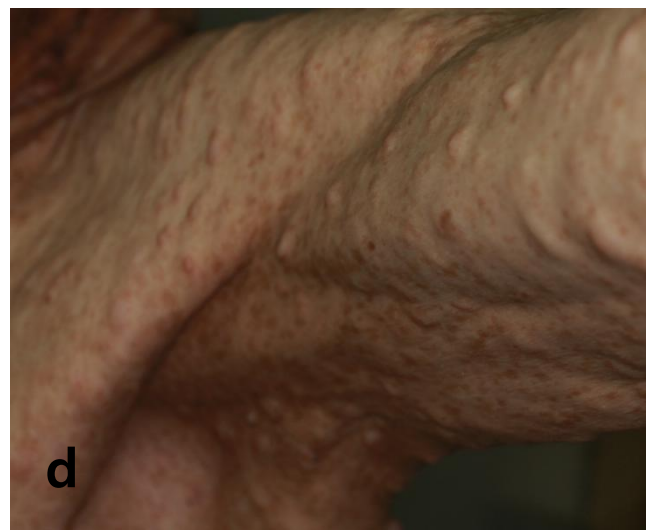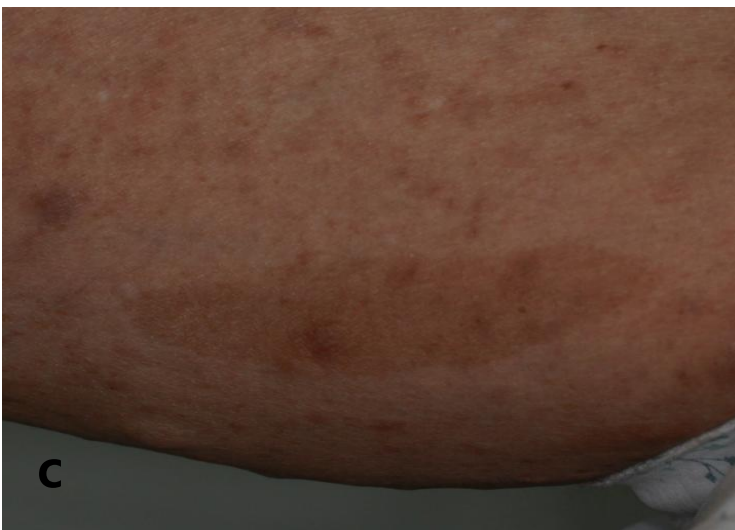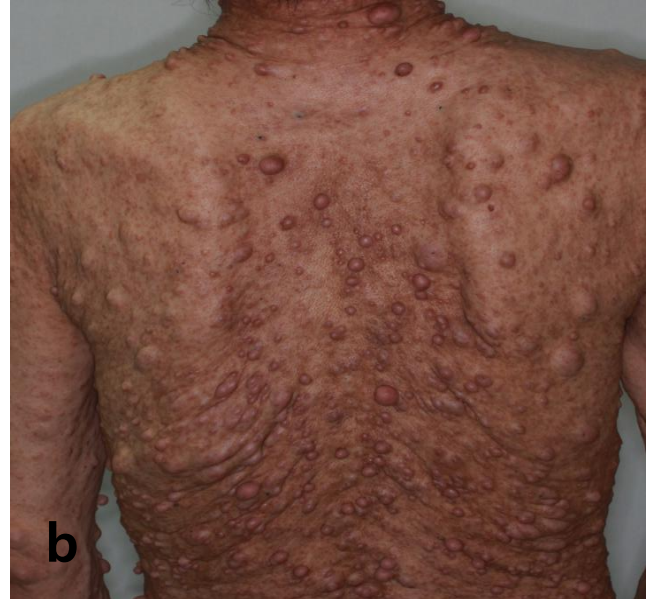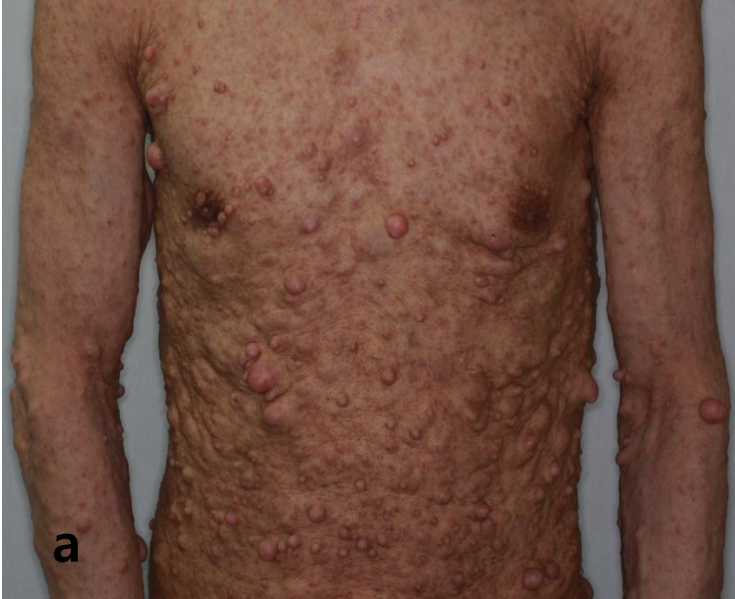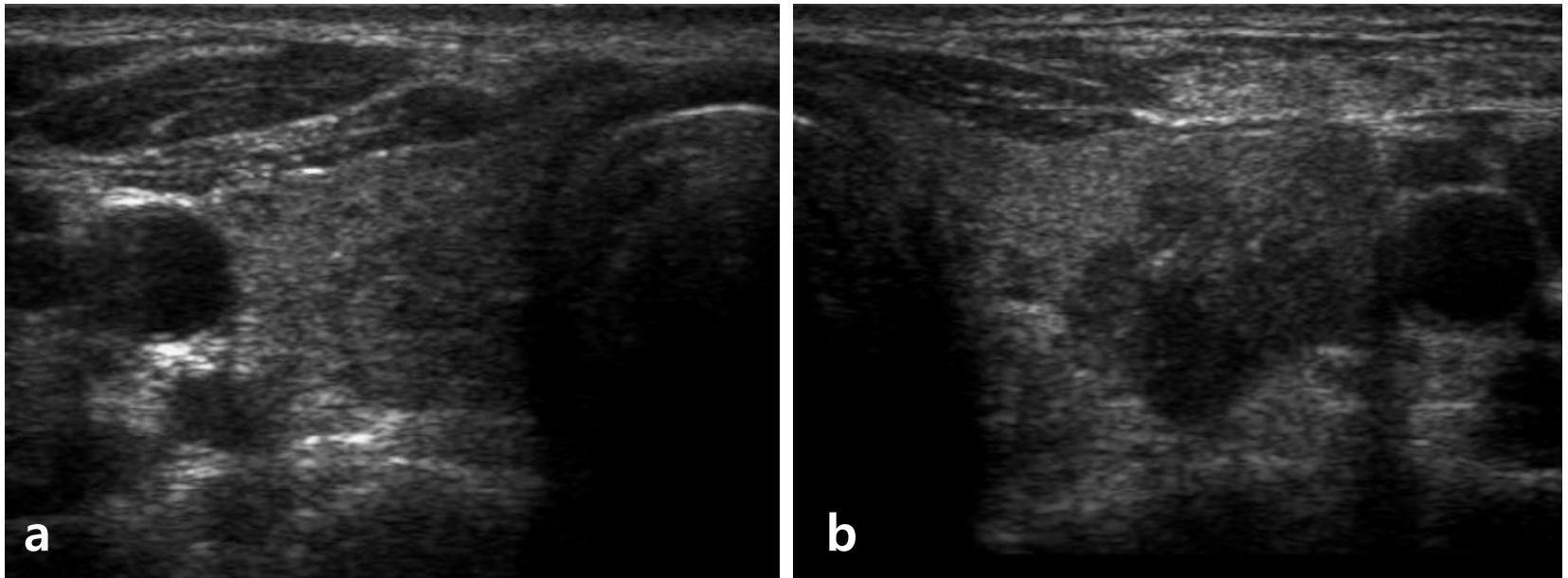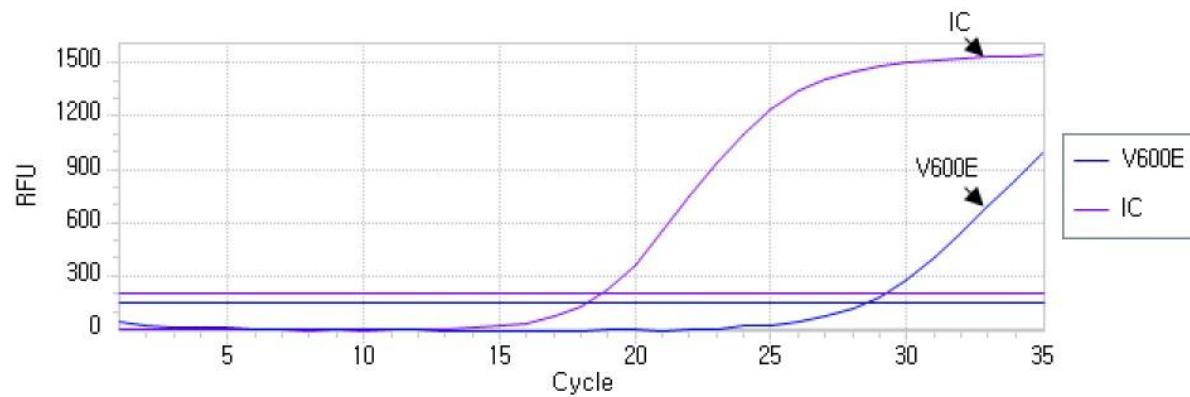


**Figure 2.** Transverse US image of thyroid nodules. **a** In the right lobe, a  $0.79 \times 0.75$  cm sized hypoechoic and homogeneous nodule with halo was observed. **b** In the left lobe, a markedly hypoechoic  $1.25 \times 1.38$  cm sized nodule with irregular margins, microcalcification, and extracapsular extension was observed in the middle portion.



**Figure 3.** Detection of V600E mutation using Anyplex™ *BRAF* real time detection (seegene, Daejeon, Korea) which allows for simultaneous amplification of total nucleic acid of V600E and internal control (human beta globin gene).