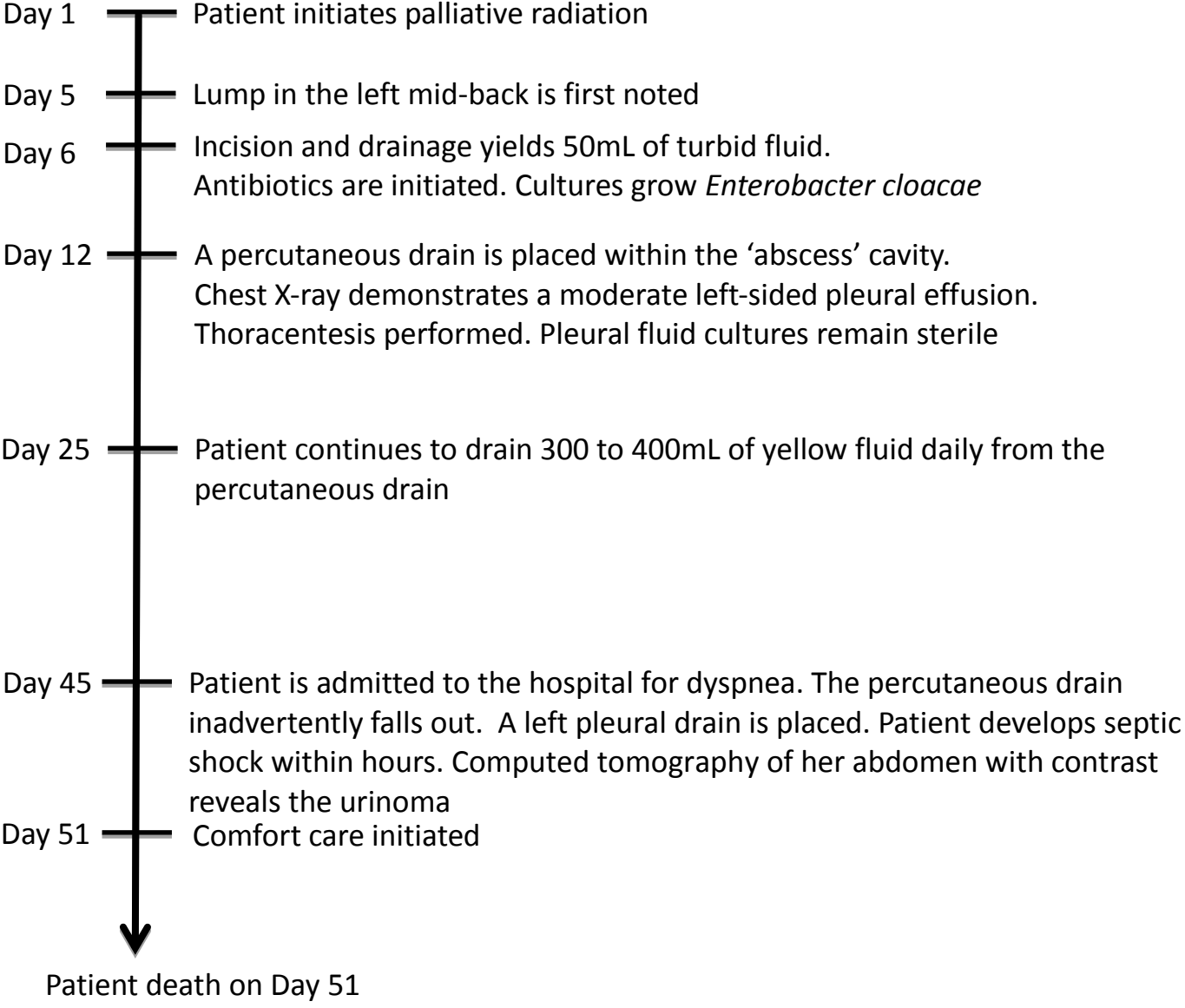
Day 1
Patient initiates palliative radiation
Day 5
Lump in the left mid-back is first noted
Day 6
Incision and drainage yields 50mL of turbid fluid.
Antibiotics are initiated. Cultures grow *Enterobacter cloacae*
Day 12
A percutaneous drain is placed within the 'abscess' cavity.
Chest X-ray demonstrates a moderate left-sided pleural effusion.
Thoracentesis performed. Pleural fluid cultures remain sterile
Day 25
Patient continues to drain 300 to 400mL of yellow fluid daily from the percutaneous drain
Day 45
Patient is admitted to the hospital for dyspnea. The percutaneous drain inadvertently falls out. A left pleural drain is placed. Patient develops septic shock within hours. Computed tomography of her abdomen with contrast reveals the urinoma
Day 51
Comfort care initiated
Patient death on Day 51