



*The Intensive Connection*

# E-learning module: Stages of pressure injuries

# Classification of pressure injuries

**The International Pressure Injury Category System (2009) was developed by:**

- the National Pressure Ulcer Advisory Panel (NPUAP)
- the European Pressure Ulcer Advisory Panel (EPUAP)

**and incorporated in the International Clinical Practice Guideline (2014)\* developed by:**

- the National Pressure Ulcer Advisory Panel (NPUAP)
- the European Pressure Ulcer Advisory Panel (EPUAP)
- the Pan Pacific Pressure Injury Alliance (PPPIA)



\*This consensus guideline serves as basis for this educational module

# Pressure injury

## Definition

A pressure injury is a localized injury to the skin and/or underlying tissue usually over a bony prominence, as a result of pressure, or pressure in combination with shear.

A number of contributing or confounding factors are also associated with pressure injuries; the significance of these factors is yet to be elucidated.

# Stages\* of pressure injuries

- Stage I: Nonblanchable Erythema
- Stage II: Partial Thickness Skin Loss
- Stage III: Full Thickness Skin Loss
- Stage IV: Full Thickness Tissue Loss
- Unstageable: Depth Unknown
- Suspected Deep Tissue Injury: Depth Unknown



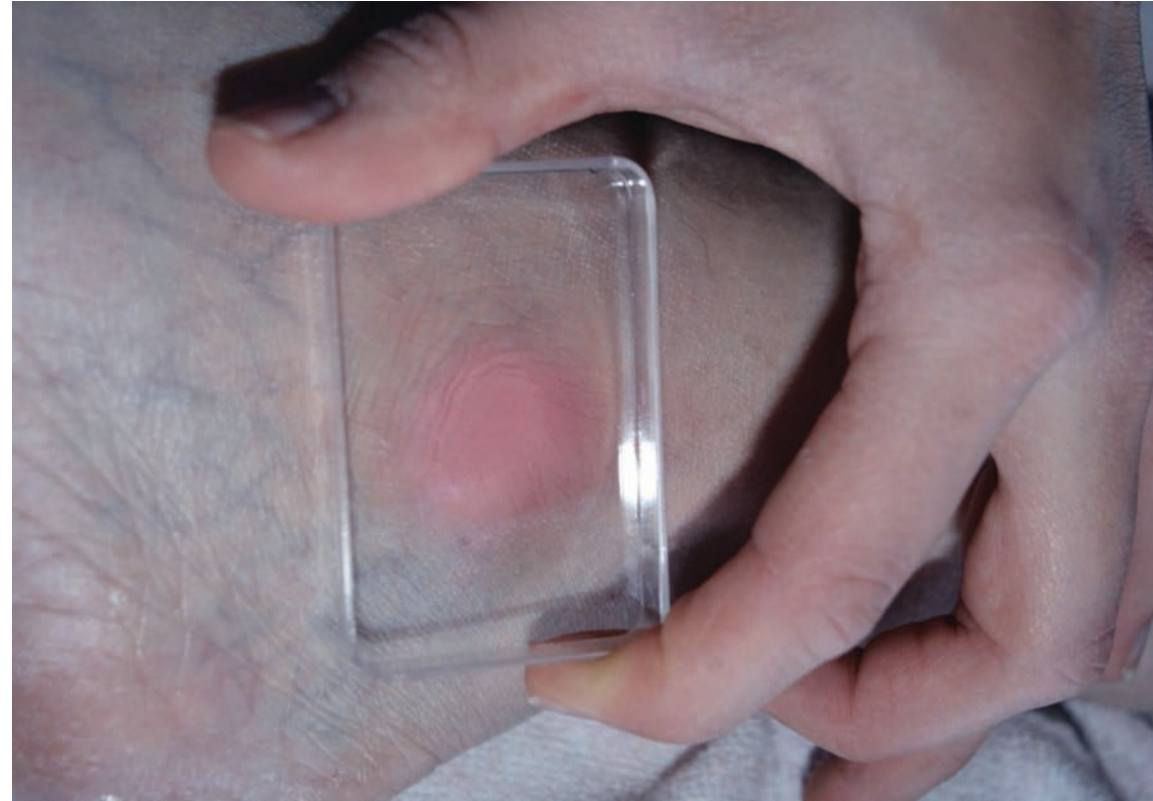
\*For convenience sake, the term “Stage” is used in this educational module when referring to the term “Category/Stage” used in the NPUAP/EPUAP Clinical Practice Guideline

# Stage I: Nonblanchable Erythema

Definition: intact skin with nonblanchable redness of a localized area, usually over a bony prominence

The area may be painful, firm, soft, warmer or cooler compared to surrounding tissue. Individuals with nonblanchable erythema are particularly at risk for developing higher stages of pressure injuries.

May be difficult to detect in individuals with darkly pigmented skin: it may be recommended to rely on assessment of skin temperature, changes in tissue consistency and pain rather than identification of nonblanchable erythema.

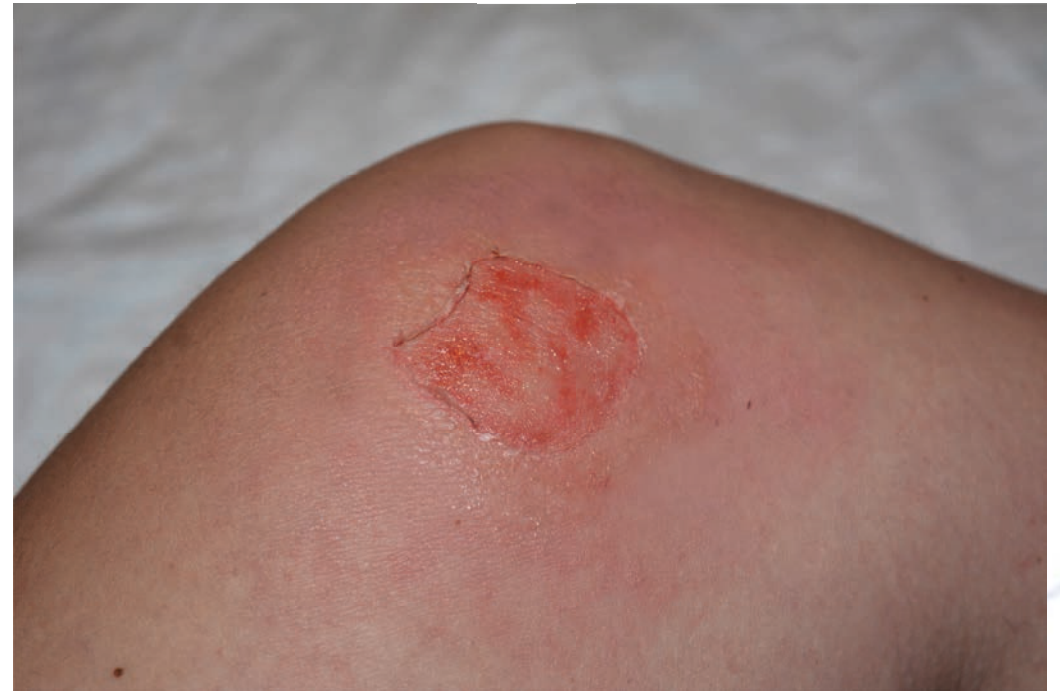

# Stage II: Partial Thickness Skin Loss

Definition: partial thickness loss of dermis presenting as a shiny or dry shallow open ulcer with a red pink wound bed without slough or bruising. May also present as an intact or open/ruptured serum-filled blister

In individuals with darkly pigmented skin, assess:

- skin heat
- skin tenderness
- change in tissue consistency
- pain



This stage should **not be used** to describe skin tears, tape burns, perineal dermatitis, maceration or excoriation

# Stage III: Full Thickness Skin Loss

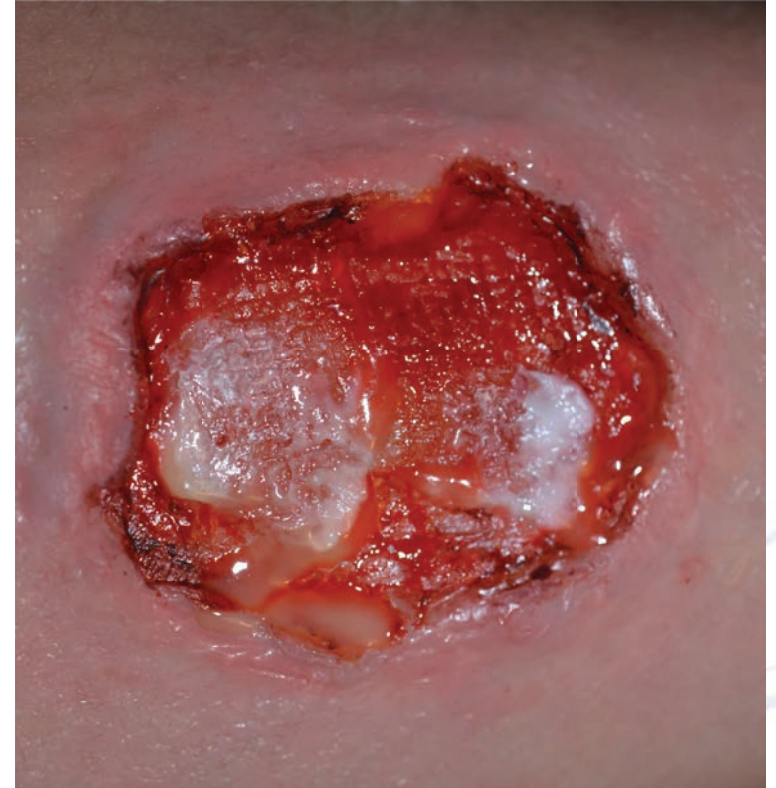Definition: full thickness tissue loss

Subcutaneous fat may be visible; bone, tendon or muscle are not exposed. Slough may be present but does not obscure the depth of tissue loss. May include undermining and tunnelling

The depth of the injury varies by anatomical location:

- shallow Stage III: often in areas with little subcutaneous tissue e.g. bridge of the nose, ear, occiput and malleolus
- extremely deep Stage III: often in areas of significant adiposity

In individuals with darkly pigmented skin: assess skin heat, skin tenderness, change in tissue consistency and pain



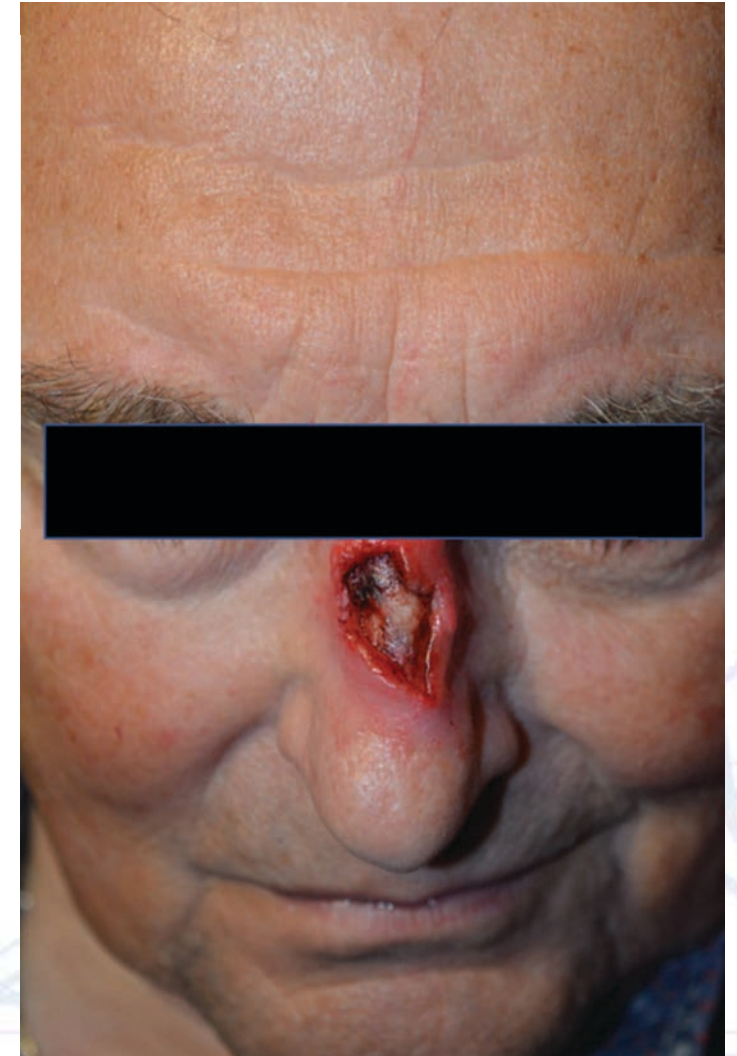# Stage IV: Full Thickness Tissue Loss

Definition: full thickness tissue loss with exposed bone, tendon or muscle (visible or directly palpable)

Depth varies by anatomical location with shallow Stage IV often observed in areas with little subcutaneous tissue e.g. bridge of the nose, ear, occiput and malleolus

Possible extension into muscle and/or supporting structures (fascia, tendon, joint capsule): risk of osteomyelitis. Slough or eschar may be present on parts of the wound bed; often with undermining and tunnelling

In individuals with darkly pigmented skin: assess skin heat, skin tenderness, change in tissue consistency and pain





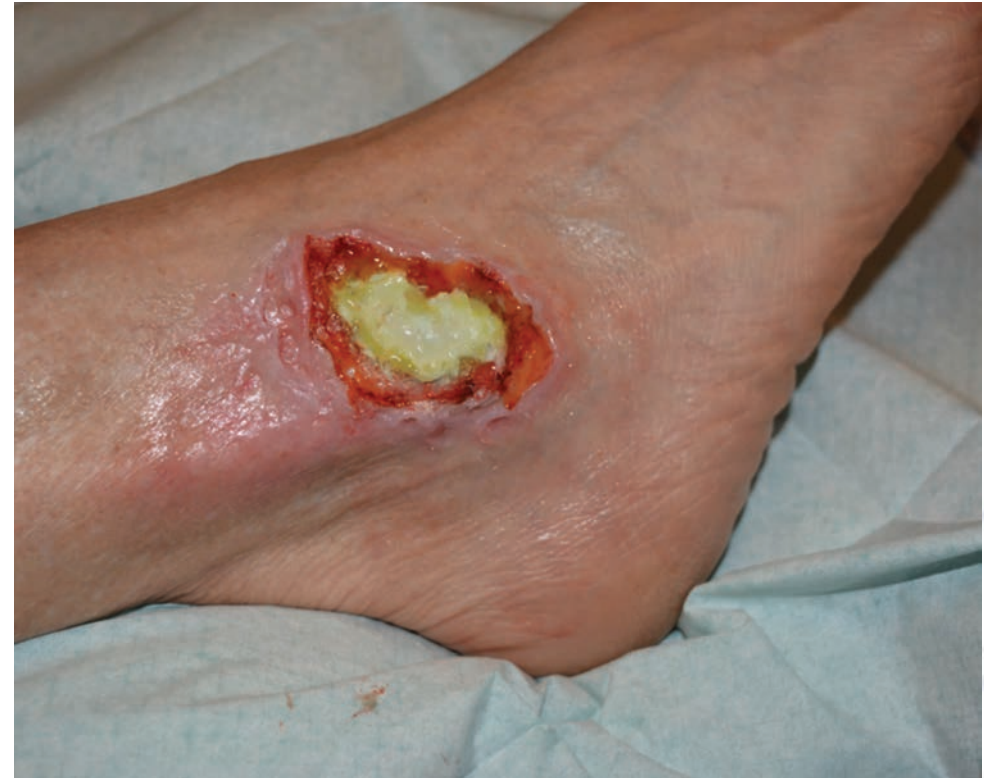# Unstageable: Depth Unknown

Definition: full thickness tissue loss in which the base of the injury is covered by slough (yellow, tan, grey, green or brown) and/or eschar (tan, brown or black) in the wound bed

Depth and stage are not to be determined until enough slough and/or eschar is removed to expose the base of the wound

Stable (dry, adherent, intact without erythema or fluctuance) eschar on the heels should not be removed ('the body's biological cover')

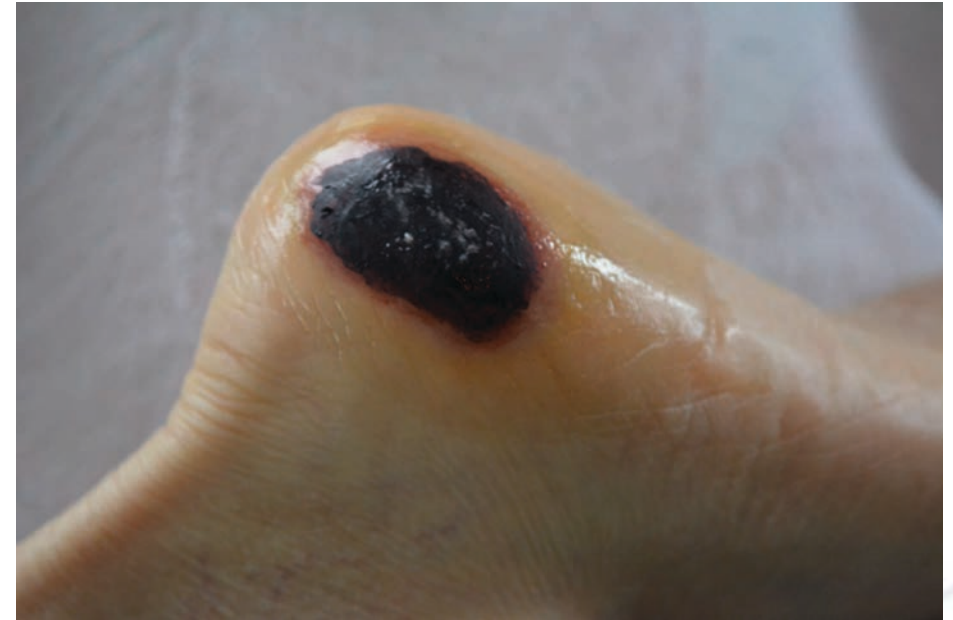In individuals with darkly pigmented skin: assess skin heat, skin tenderness, change in tissue consistency and pain



# Suspected Deep Tissue Injury: Depth Unknown

Definition: Purple or maroon localized area of discoloured intact skin or blood-filled blister due to damage of underlying soft tissue from pressure and/or shear

In individuals with darkly pigmented skin: assess skin temperature, change in tissue consistency and pain



## **Potential evolution of the wound:**

- thin blister over a dark wound bed, covered by thin eschar
- rapid deterioration
- exposure of additional layers of tissue
- regardless of optimal treatment

## **Surrounding area:**

- painful
- firm
- mushy
- boggy
- warmer/cooler

# Inspection of the skin: Methods

Inspection of the skin for erythema in patients 'at risk' of developing a pressure injury:

- cause and extent of erythema
- skin redness: blanchable or nonblanchable? → finger or disc method

## **Finger pressure method:**

a finger is pressed on the erythema for three seconds and blanching is assessed following removal of the finger

## **Transparent disk method:**

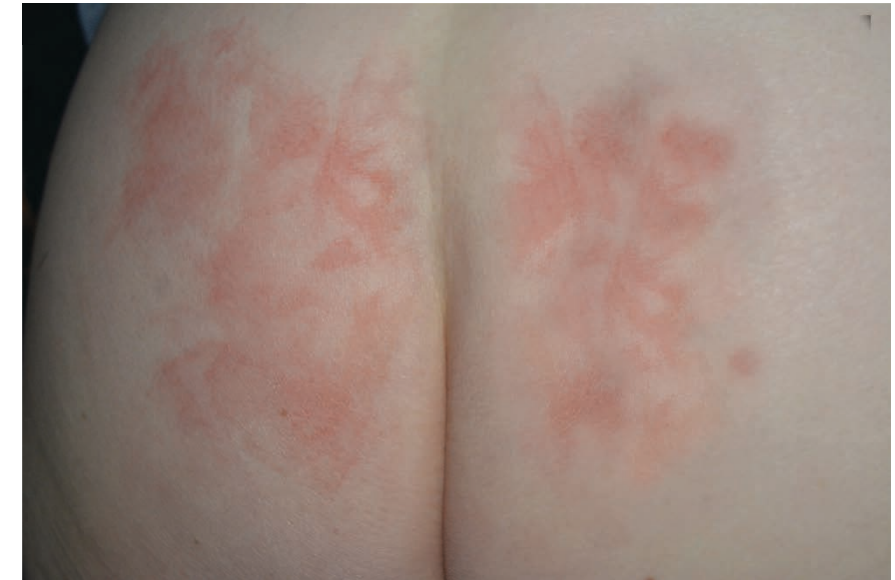a transparent disk is used to apply pressure equally over an area of erythema, and blanching can be observed underneath the disk during its application.

# Attention: MASD is NOT pressure injury

Moisture-associated skin damage (MASD) is commonly confused with pressure injury, while origin and treatment differ completely.

Definition: MASD is inflammation and erosion of the skin caused by prolonged exposure to various sources of moisture, including urine or stool, perspiration, wound exudate, mucus, or saliva.

In relation to pressure injuries, MASD mostly appears as Incontinence Associated Dermatitis (IAD), which is typical for the sacral area.



	Pressure injury	Moisture-associated skin damage
Etiology	Pressure - shear	Prolonged exposure to sources of moisture
Location	Usually over a bony prominence	Anywhere moisture can accumulate
Distribution	Localized area, distinct edges	Diffuse different spots, diffuse irregular edges
Depth	Partial or full thickness skin loss	Superficial - partial thickness skin loss

# Differentiate pressure injuries also from other wound types

Besides MASD, more wound types may be incorrectly classified as pressure injury. Some common examples are:

- venous ulcers
- neuropathic ulcers
- skin tears
- intertrigo

# Literature

Gray M., Black J.M., Baharestani M. M. et al.; Moisture-Associated Skin Damage Overview and Pathophysiology. *J Wound Ostomy Continence Nurs.* 2011; 38(3): 233-241.

Gray M., Bliss D.Z., Doughty D.B. et al.; Incontinence-associated Dermatitis. A Consensus. *J Wound Ostomy Continence Nurs.* 2007; 34(1): 45-54.

National Pressure Ulcer Advisory Panel, European Pressure Ulcer Advisory Panel and Pan Pacific Pressure Injury Alliance. *Prevention and Treatment of Pressure Ulcers: Quick Reference Guide.* Emily Haesler (Ed.). Cambridge Media: Osborne Park, Western Australia; 2014.

Zulkowski K. Diagnosing and Treating Moisture-Associated Skin Damage. *Adv Skin Wound Care.* 2012; 25(5): 231-236.

# Test your knowledge

The next slides will help you to check if you master the contents of this module.

There are 22 slides with pictures representing different stages of pressure injuries and moisture-associated skin damage (MASD). It is up to you to classify each pressure injury correctly according to the NPUAP/EPUAP classification and to recognize MASD as a non-pressure injury related wound type. Each slide with picture is followed by a slide that provides the correct answer.

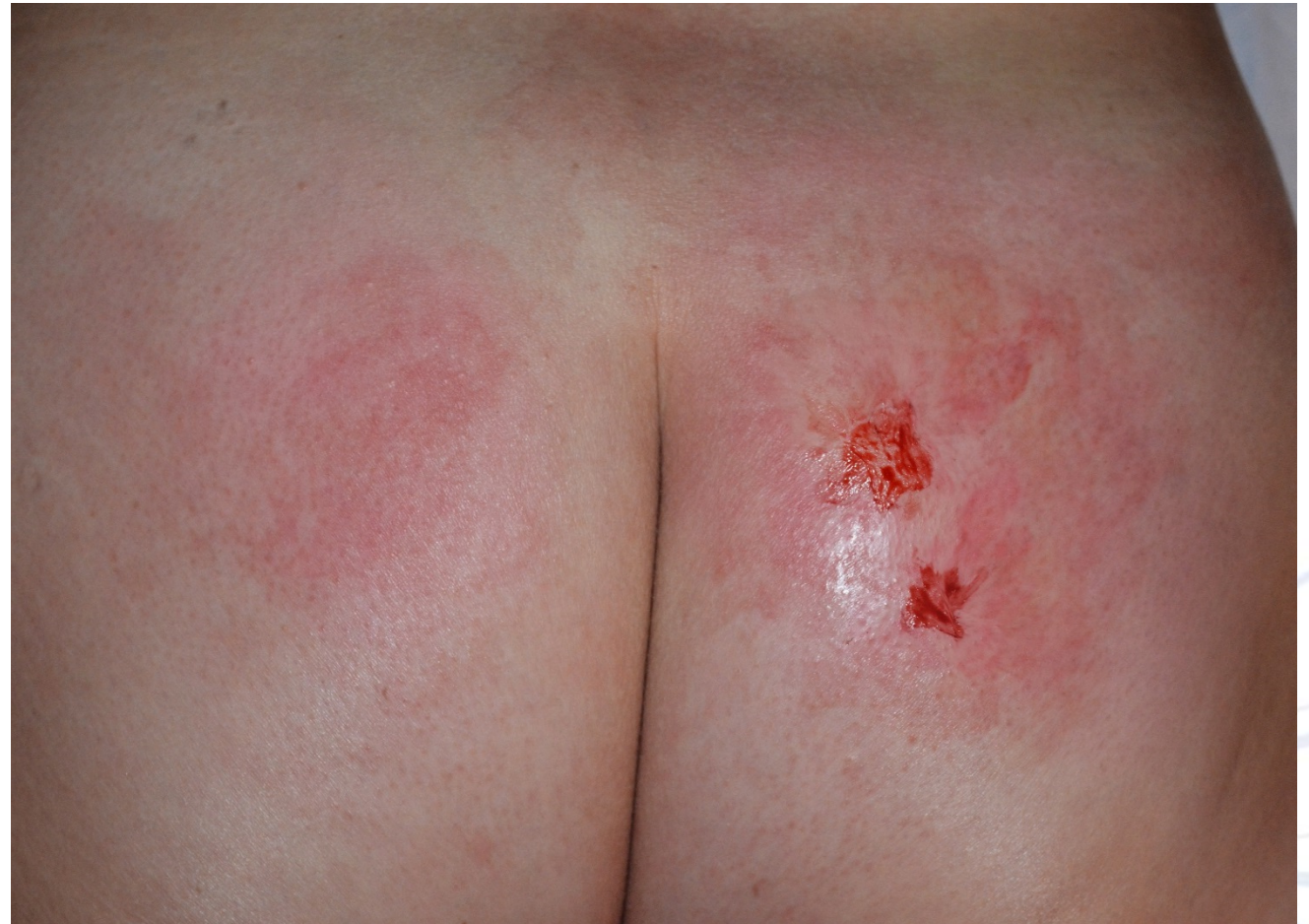Although we tried to use representative photographs for this test, we are well aware that it is not obvious to evaluate stages of pressure injuries without relevant clinical information.

**Good luck!**

# Question 1

What is this?

- Stage I pressure injury
- Stage II pressure injury
- Stage III pressure injury
- Stage IV pressure injury
- Unstageable pressure injury
- Suspected Deep Tissue Injury
- Moisture-associated skin damage





# Answer

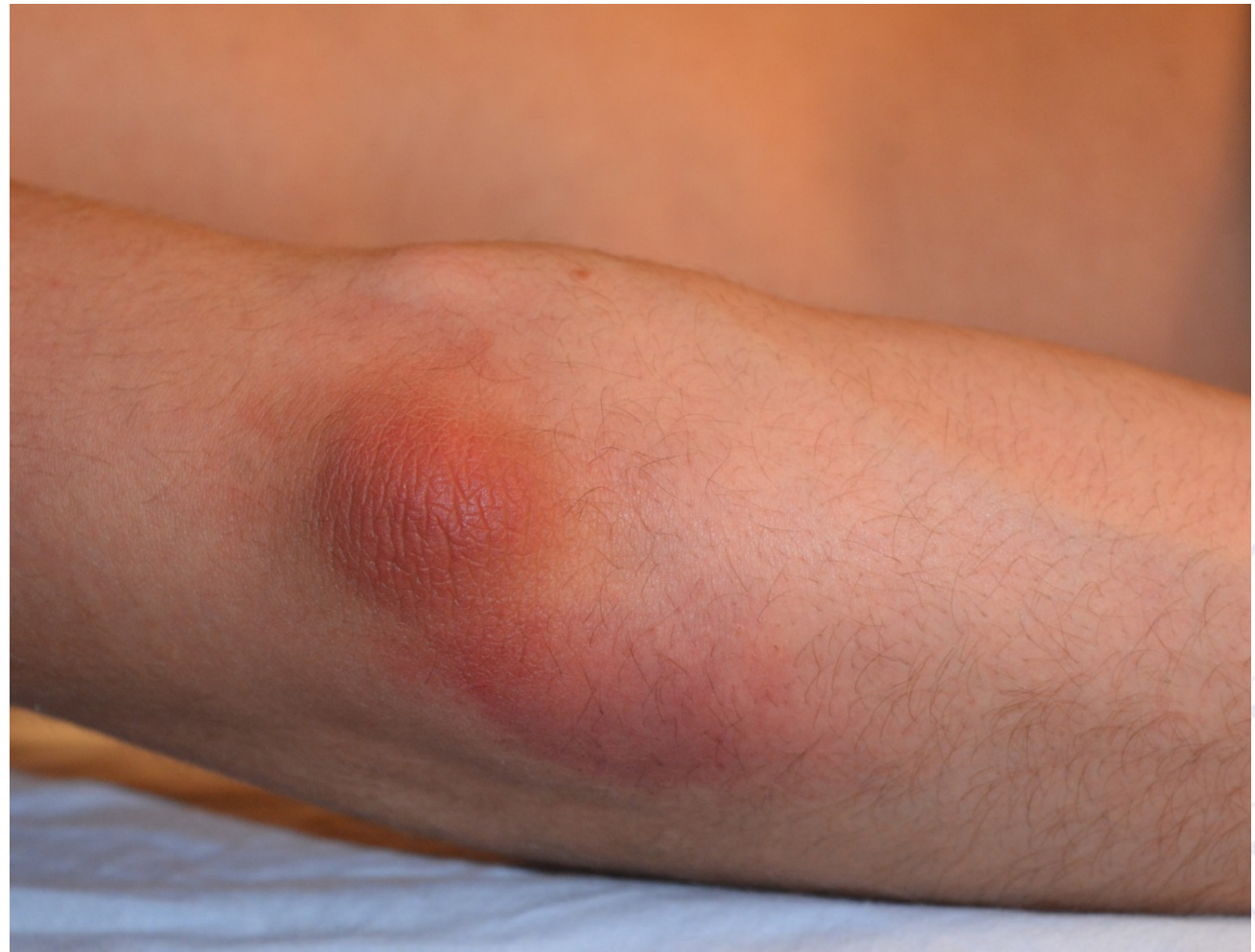Correct answer: moisture-associated skin damage (MASD), possibly incontinence-related.

Explanation: there is a noticeable erythema of the skin. Skin damage is superficial and the edges are irregular. There is also some degree of maceration present, probably due to friction. The effects of friction on a wet skin are more damaging than on the dry skin.

# Question 2

What is this?

- Stage I pressure injury
- Stage II pressure injury
- Stage III pressure injury
- Stage IV pressure injury
- Unstageable pressure injury
- Suspected Deep Tissue Injury
- Moisture-associated skin damage



# Answer

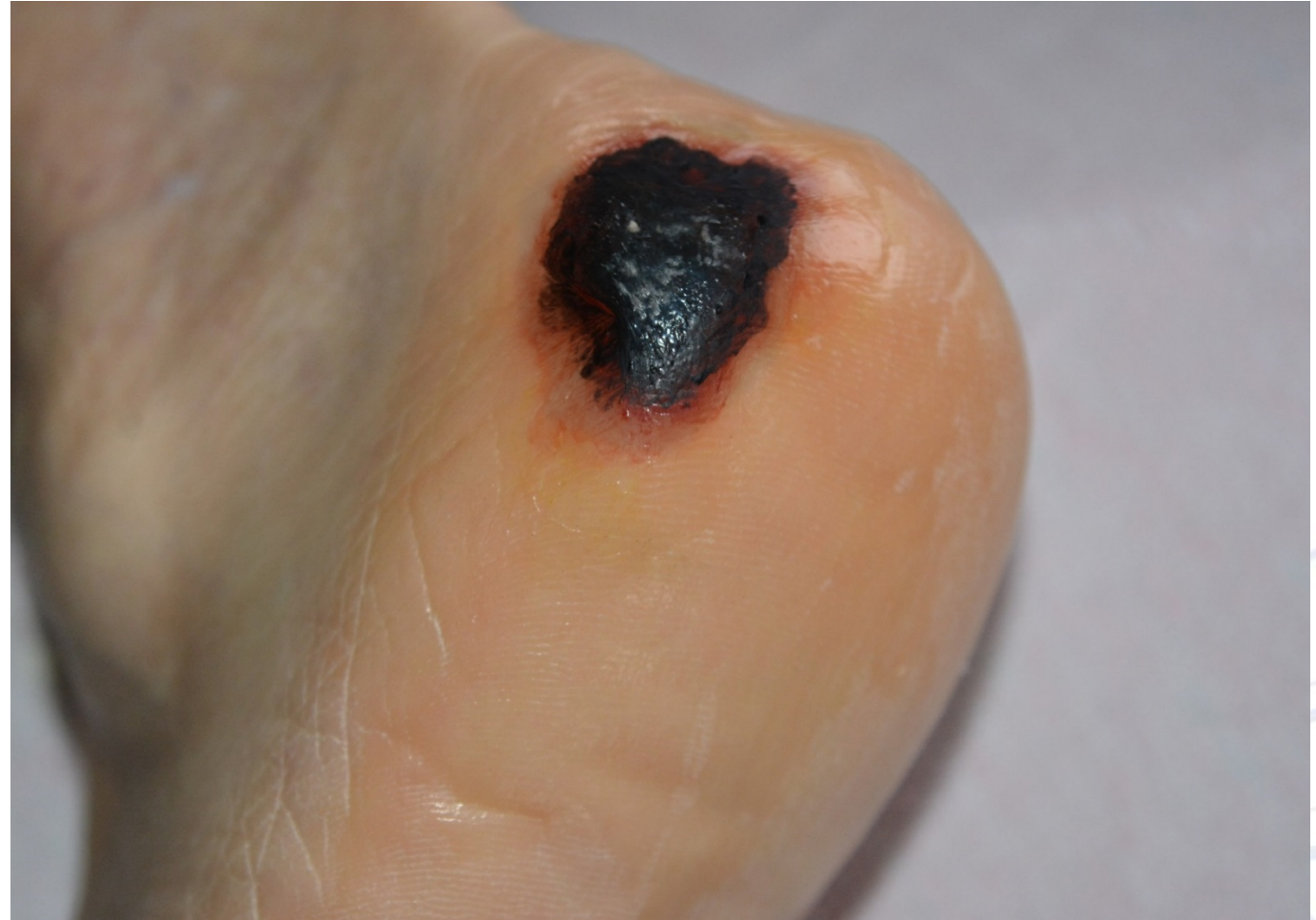Correct answer: Stage I pressure injury

Explanation: the skin is intact and the erythema is nonblanchable.

# Question 3

What is this?

- Stage I pressure injury
- Stage II pressure injury
- Stage III pressure injury
- Stage IV pressure injury
- Unstageable pressure injury
- Suspected Deep Tissue Injury
- Moisture-associated skin damage



# Answer

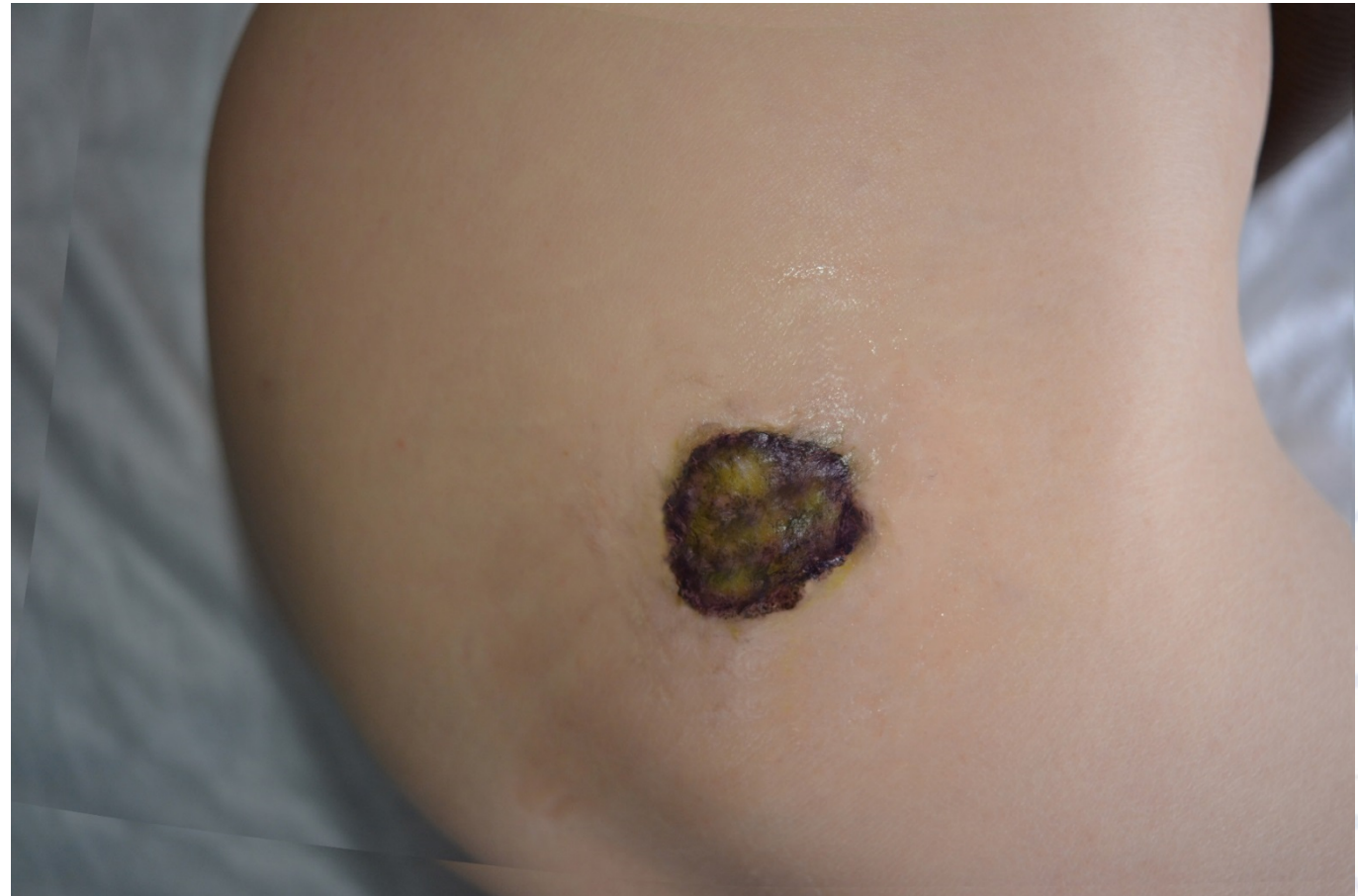Correct answer: suspected deep tissue injury

Explanation: a dark eschar covers the localized wound area. The skin surrounding the eschar is coloured maroon. The visible skin is intact. We can assume that the underlying soft tissue has been damaged.

# Question 4

What is this?

- Stage I pressure injury
- Stage II pressure injury
- Stage III pressure injury
- Stage IV pressure injury
- Unstageable pressure injury
- Suspected Deep Tissue Injury
- Moisture-associated skin damage



# Answer

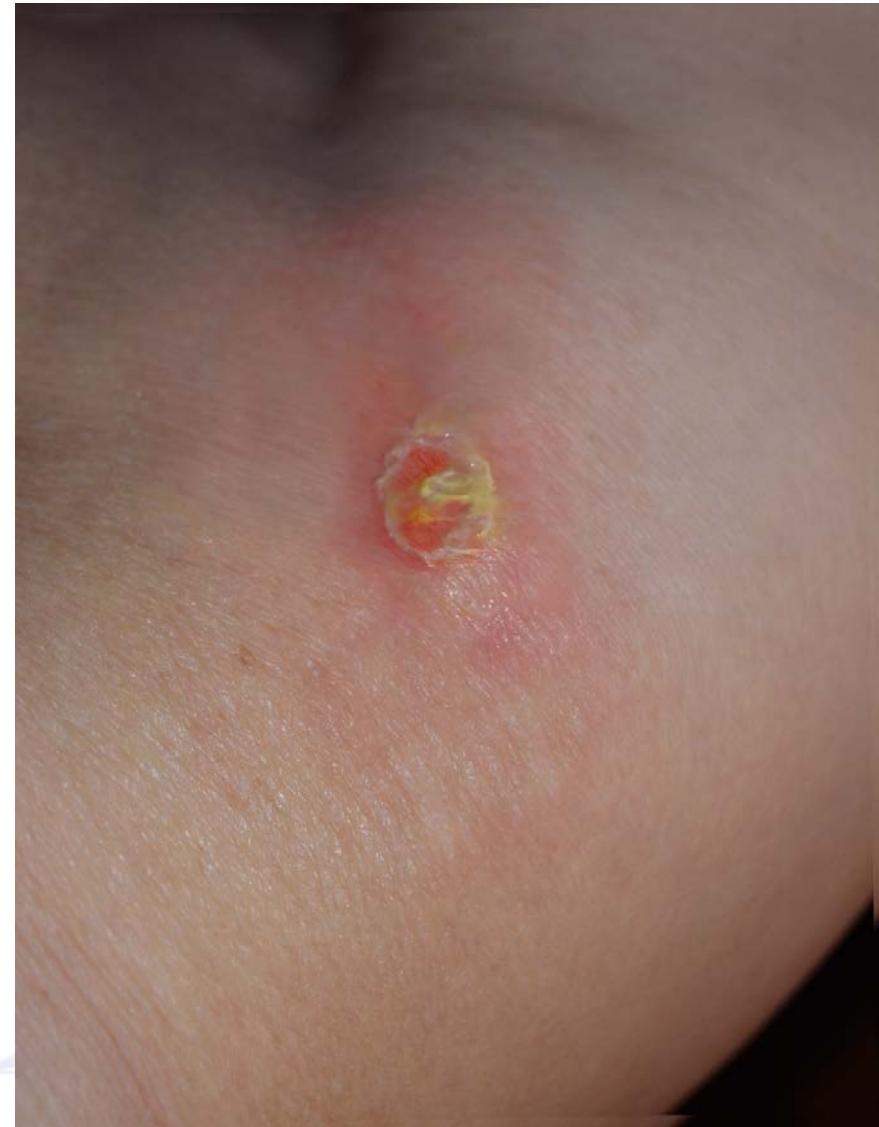Correct answer: suspected deep tissue injury

Explanation: a necrotic eschar covers the injury. The visible skin is intact. We can assume that the underlying soft tissue has been damaged. To determine the status of underlying tissue, the eschar has to be removed first.

# Question 5

What is this?

- Stage I pressure injury
- Stage II pressure injury
- Stage III pressure injury
- Stage IV pressure injury
- Unstageable pressure injury
- Suspected Deep Tissue Injury
- Moisture-associated skin damage





# Answer

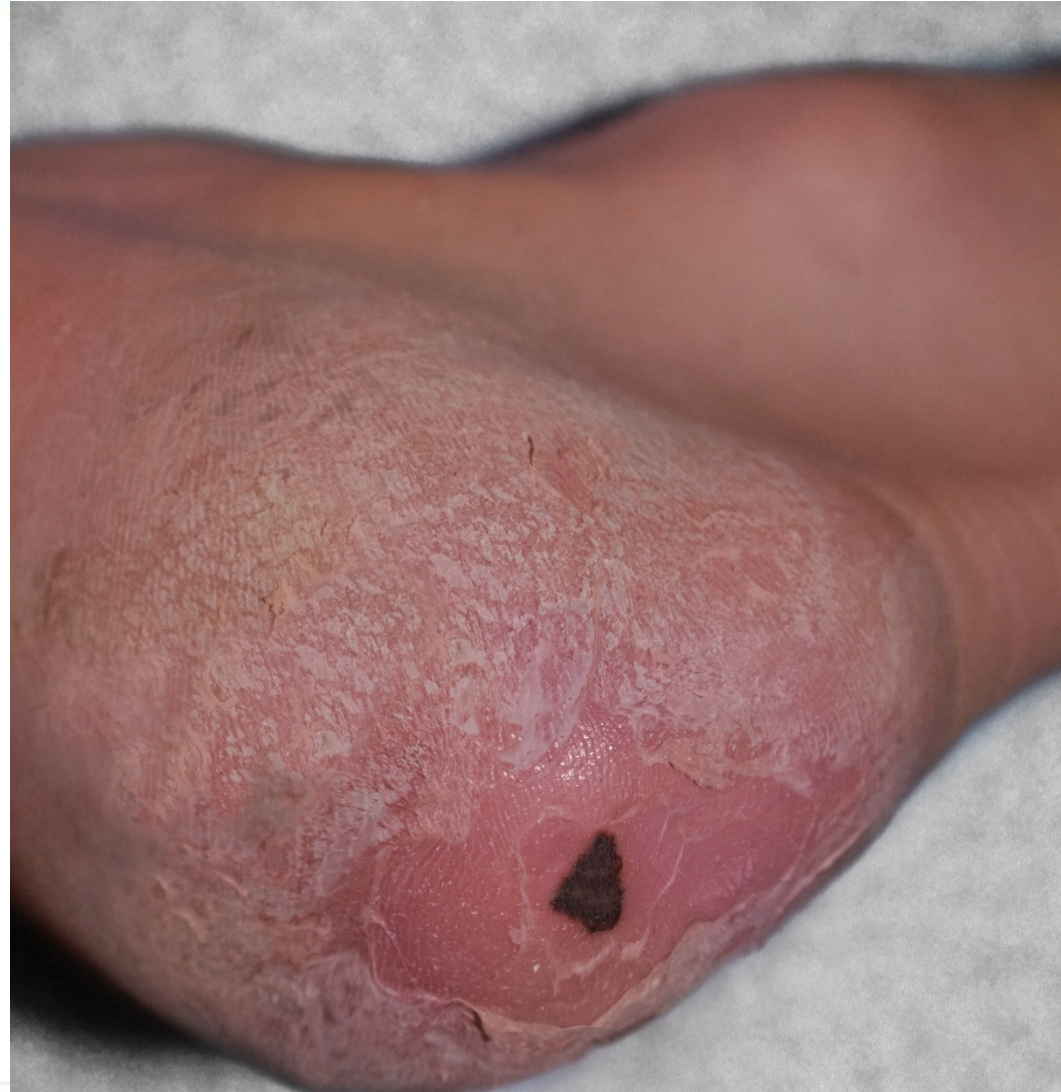Correct answer: Stage III pressure injury

Explanation: there is a full thickness tissue loss with no exposition of the bone. Slough is present without interfering with the examination of the tissue loss. This is a shallow stage III injury because the tissue damage is on the iliac crest where there is little/no subcutaneous tissue.

# Question 6

What is this?

- Stage I pressure injury
- Stage II pressure injury
- Stage III pressure injury
- Stage IV pressure injury
- Unstageable pressure injury
- Suspected Deep Tissue Injury
- Moisture-associated skin damage



# Answer

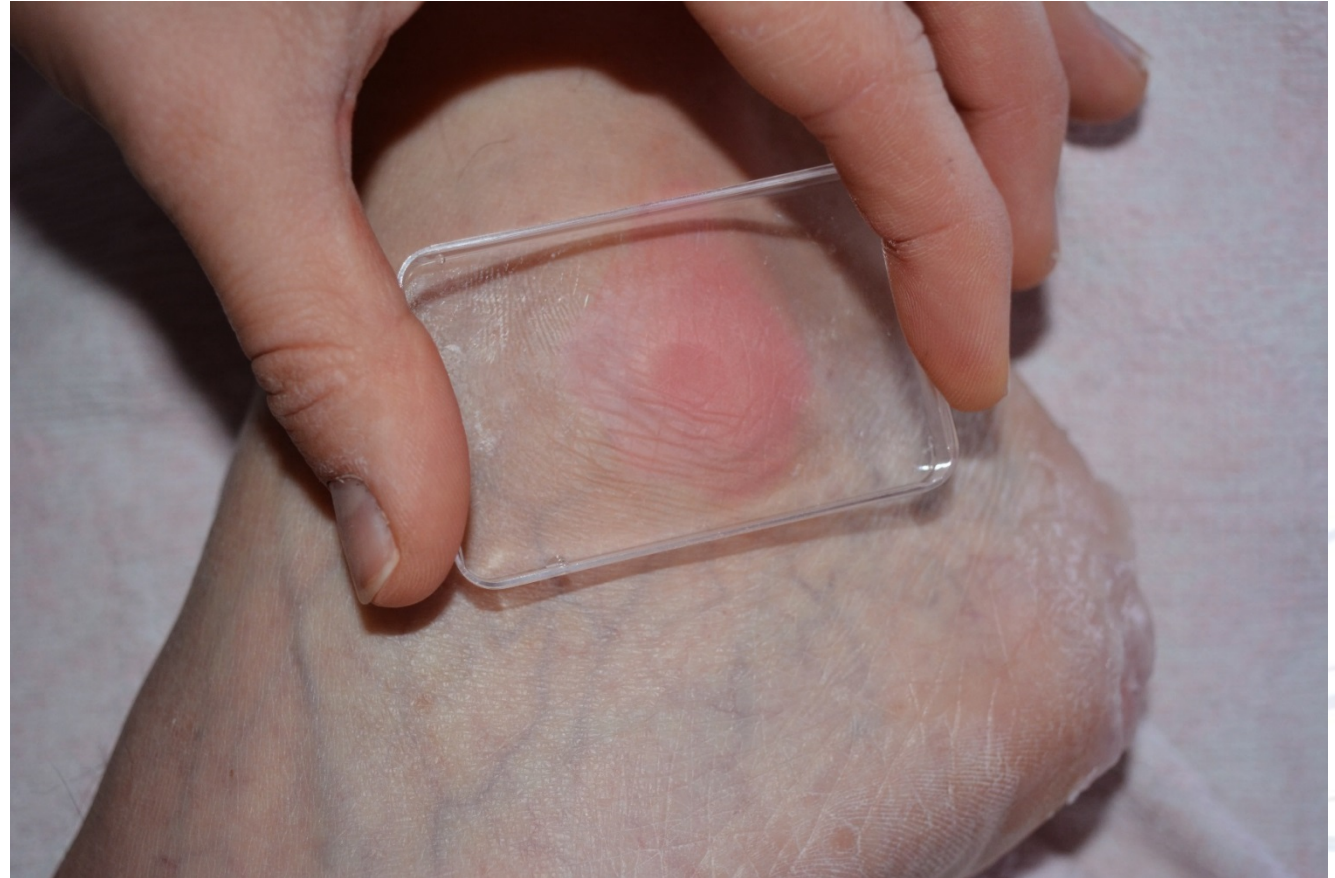
Correct answer: unstageable pressure injury

Explanation: a stable black eschar is covering the wound. It is impossible to determine how deep the wound is but probably there is a full thickness tissue loss.

# Question 7

What is this?

- Stage I pressure injury
- Stage II pressure injury
- Stage III pressure injury
- Stage IV pressure injury
- Unstageable pressure injury
- Suspected Deep Tissue Injury
- Moisture-associated skin damage



# Answer

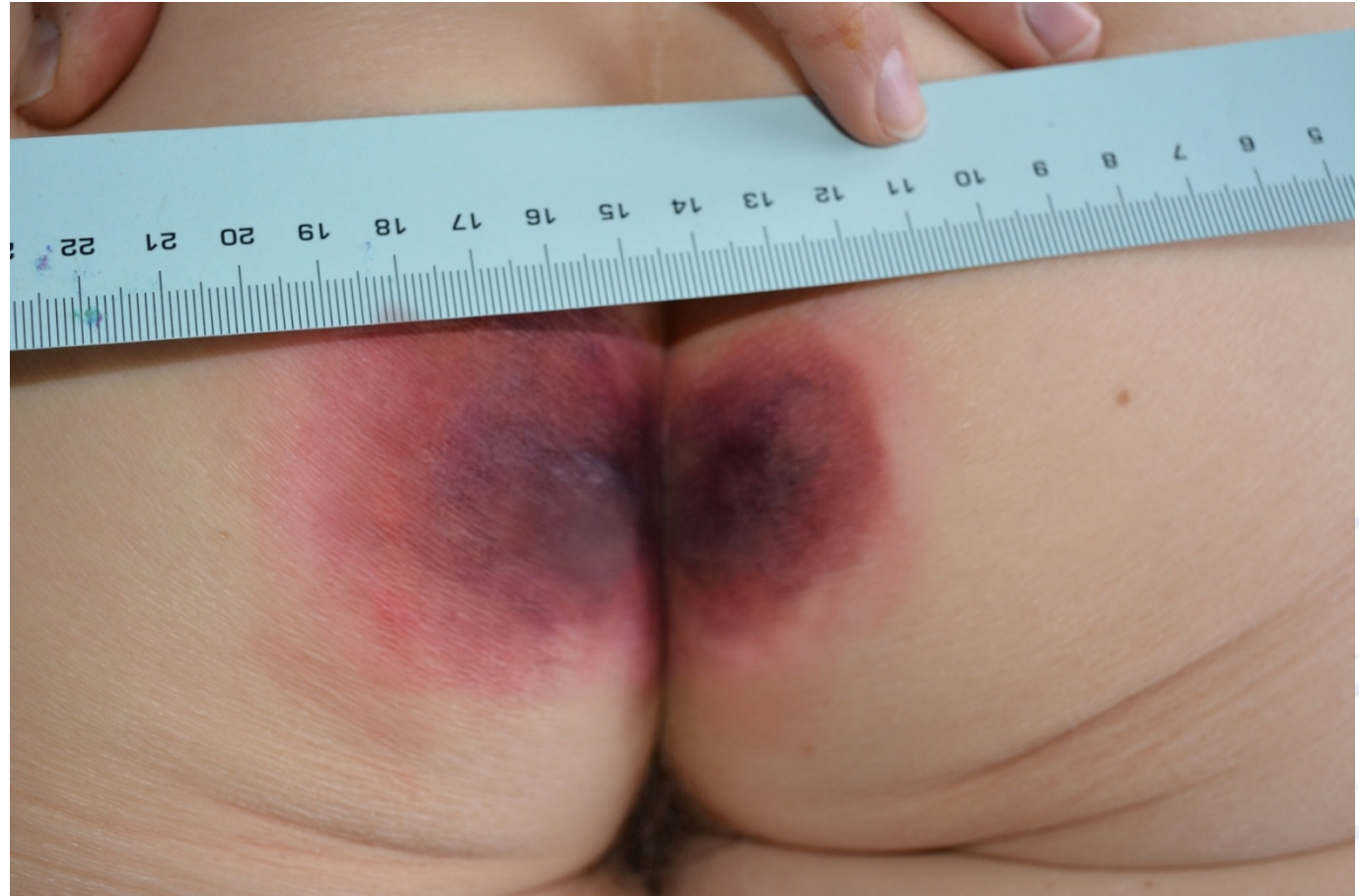Correct answer: Stage I pressure injury

Explanation: the skin is intact and the erythema is nonblanchable as determined by the transparent disk method. The ankle is a typical area for developing Stage I pressure injury because of its bony prominence.

# Question 8

What is this?

- Stage I pressure injury
- Stage II pressure injury
- Stage III pressure injury
- Stage IV pressure injury
- Unstageable pressure injury
- Suspected Deep Tissue Injury
- Moisture-associated skin damage



# Answer

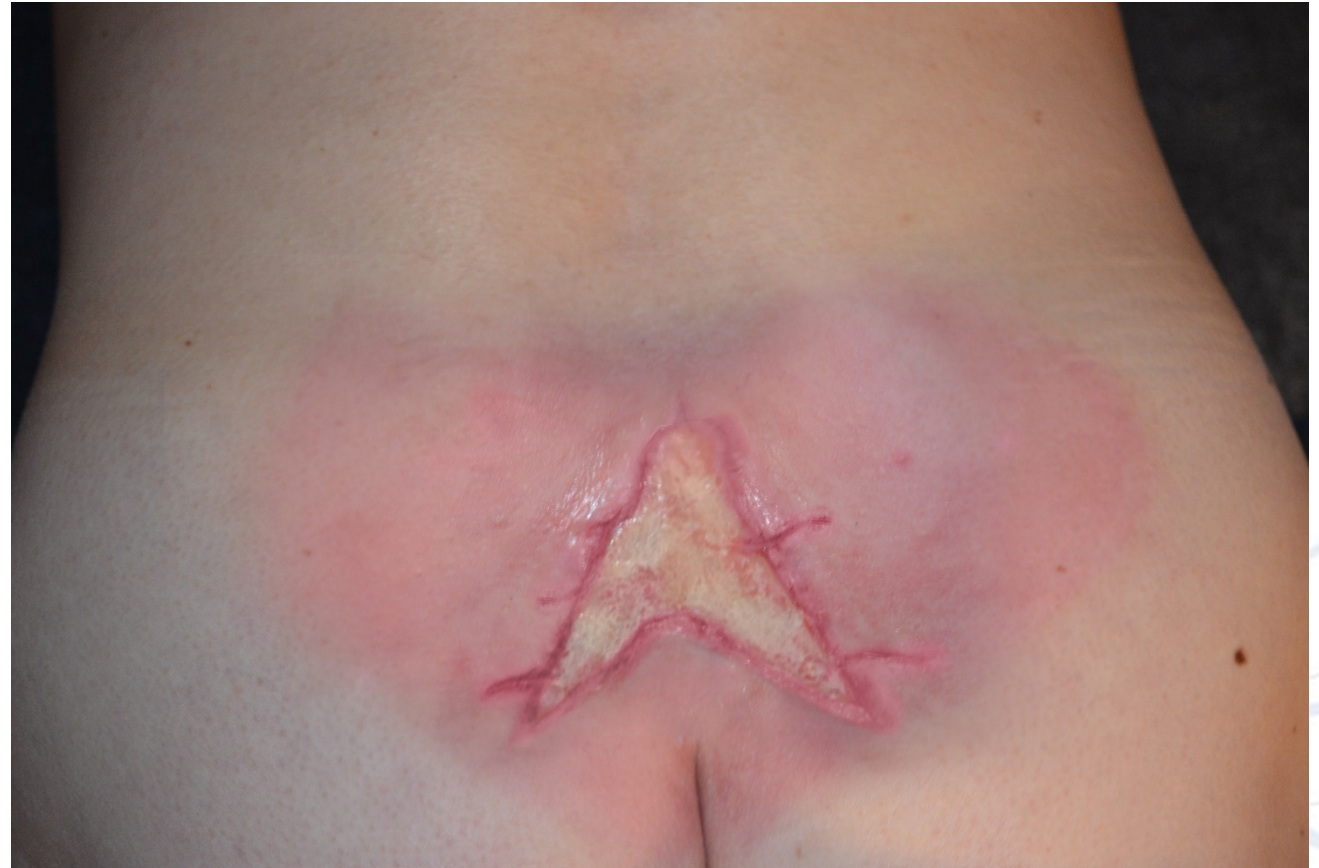Correct answer: suspected deep tissue injury

Explanation: the entire wound area is coloured purple/maroon and the skin is intact. It can be assumed that the underlying soft tissue is damaged.

# Question 9

What is this?

- Stage I pressure injury
- Stage II pressure injury
- Stage III pressure injury
- Stage IV pressure injury
- Unstageable pressure injury
- Suspected Deep Tissue Injury
- Moisture-associated skin damage





# Answer

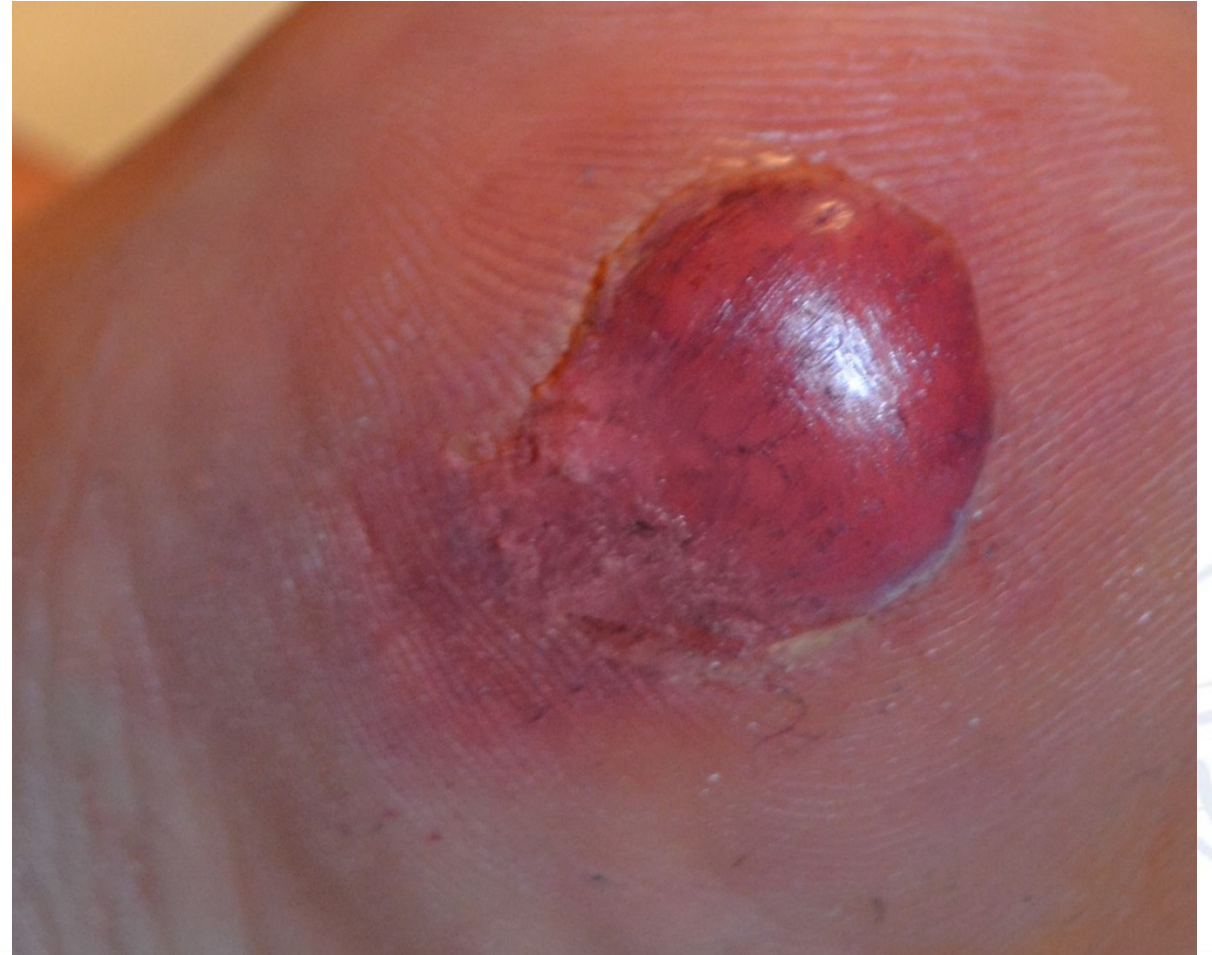Correct answer: Stage III pressure injury

Explanation: there is a full thickness tissue loss without exposition of the bone. The slough does not interfere with the examination of the tissue loss.

# Question 10

What is this?

- Stage I pressure injury
- Stage II pressure injury
- Stage III pressure injury
- Stage IV pressure injury
- Unstageable pressure injury
- Suspected Deep Tissue Injury
- Moisture-associated skin damage



# Answer

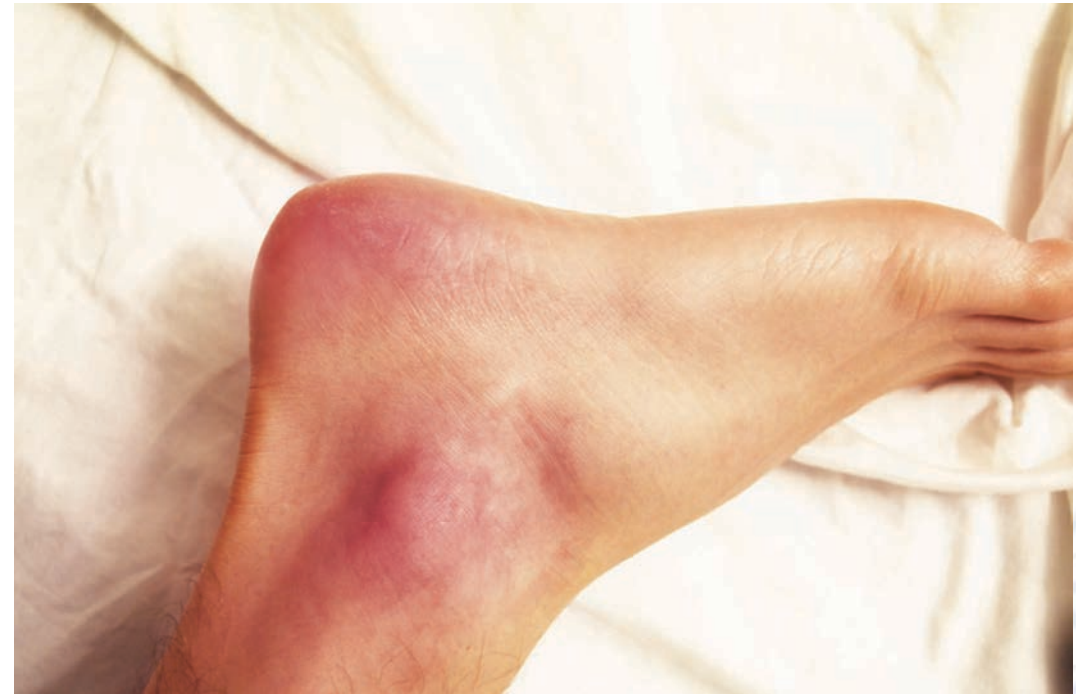Correct answer: Stage II pressure injury

Explanation: there is a partial thickness skin loss without slough or necrosis. This intact blister indicates a Stage II pressure injury.

# Question 11

What is this?

- Stage I pressure injury
- Stage II pressure injury
- Stage III pressure injury
- Stage IV pressure injury
- Unstageable pressure injury
- Suspected Deep Tissue Injury
- Moisture-associated skin damage



# Answer

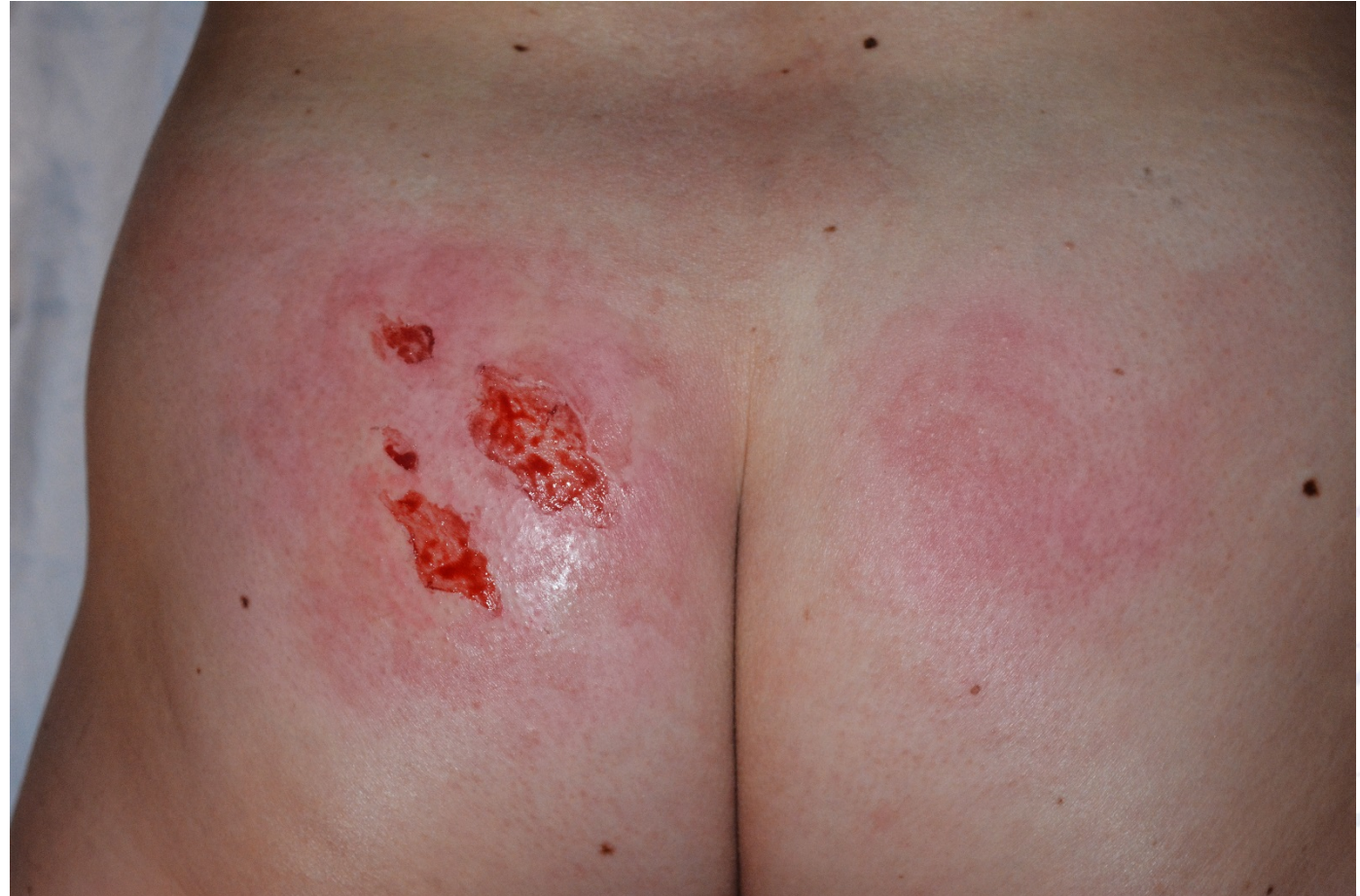Correct answer: Stage I pressure injury

Explanation: the erythema is nonblanchable. The skin of the ankle is intact. The ankle is a typical area for Stage I pressure injury development because of its bony prominence.

# Question 12

What is this?

- Stage I pressure injury
- Stage II pressure injury
- Stage III pressure injury
- Stage IV pressure injury
- Unstageable pressure injury
- Suspected Deep Tissue Injury
- Moisture-associated skin damage



# Answer

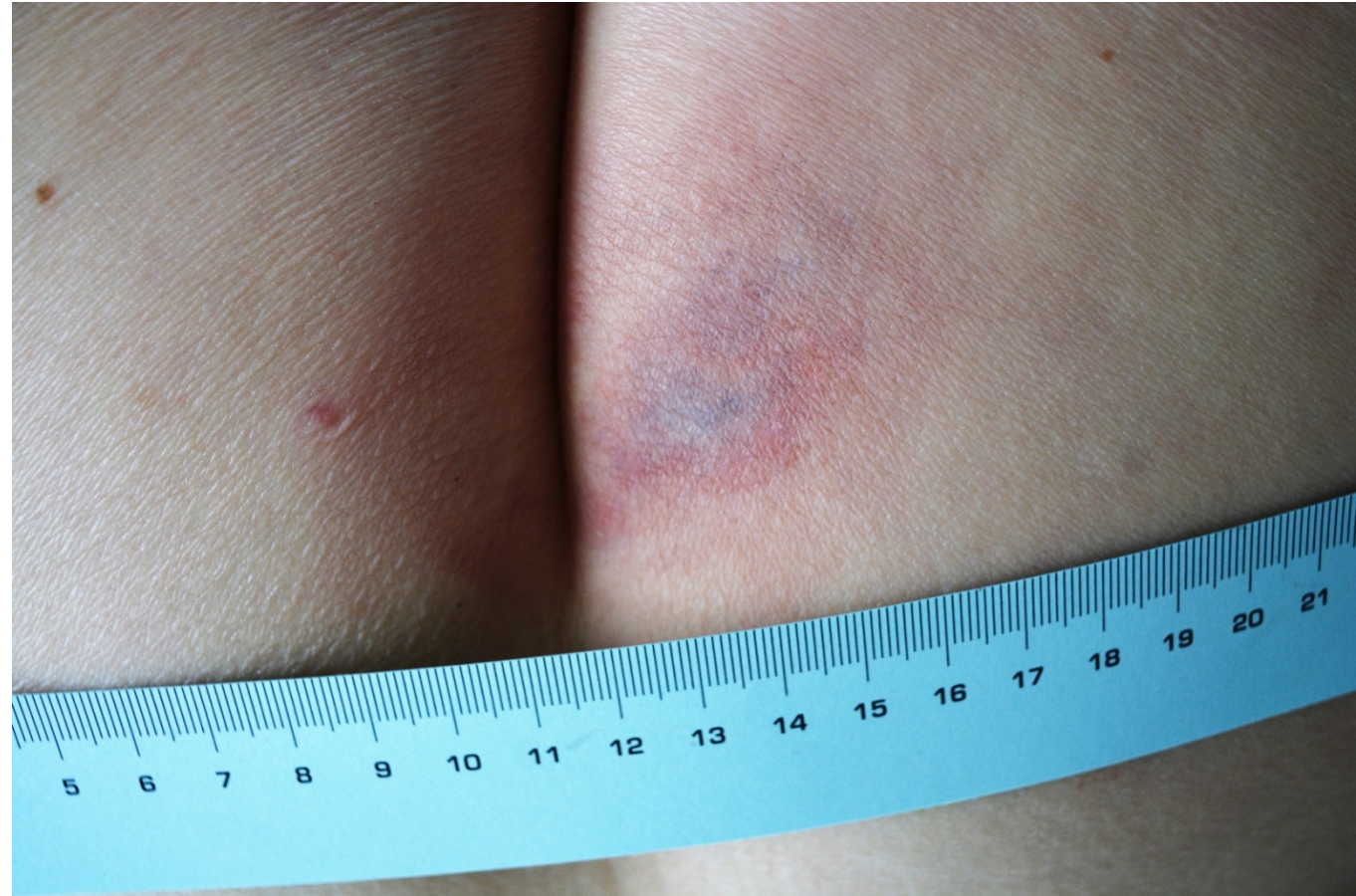Correct answer: moisture-associated skin damage (MASD), possibly incontinence-related.

Explanation: there is a noticeable erythema of the skin. Skin damage is superficial and the edges are irregular. There is also some degree of maceration present, probably due to friction. The effects of friction on a wet skin are more damaging than on the dry skin.

# Question 13

What is this?

- Stage I pressure injury
- Stage II pressure injury
- Stage III pressure injury
- Stage IV pressure injury
- Unstageable pressure injury
- Suspected Deep Tissue Injury
- Moisture-associated skin damage





# Answer

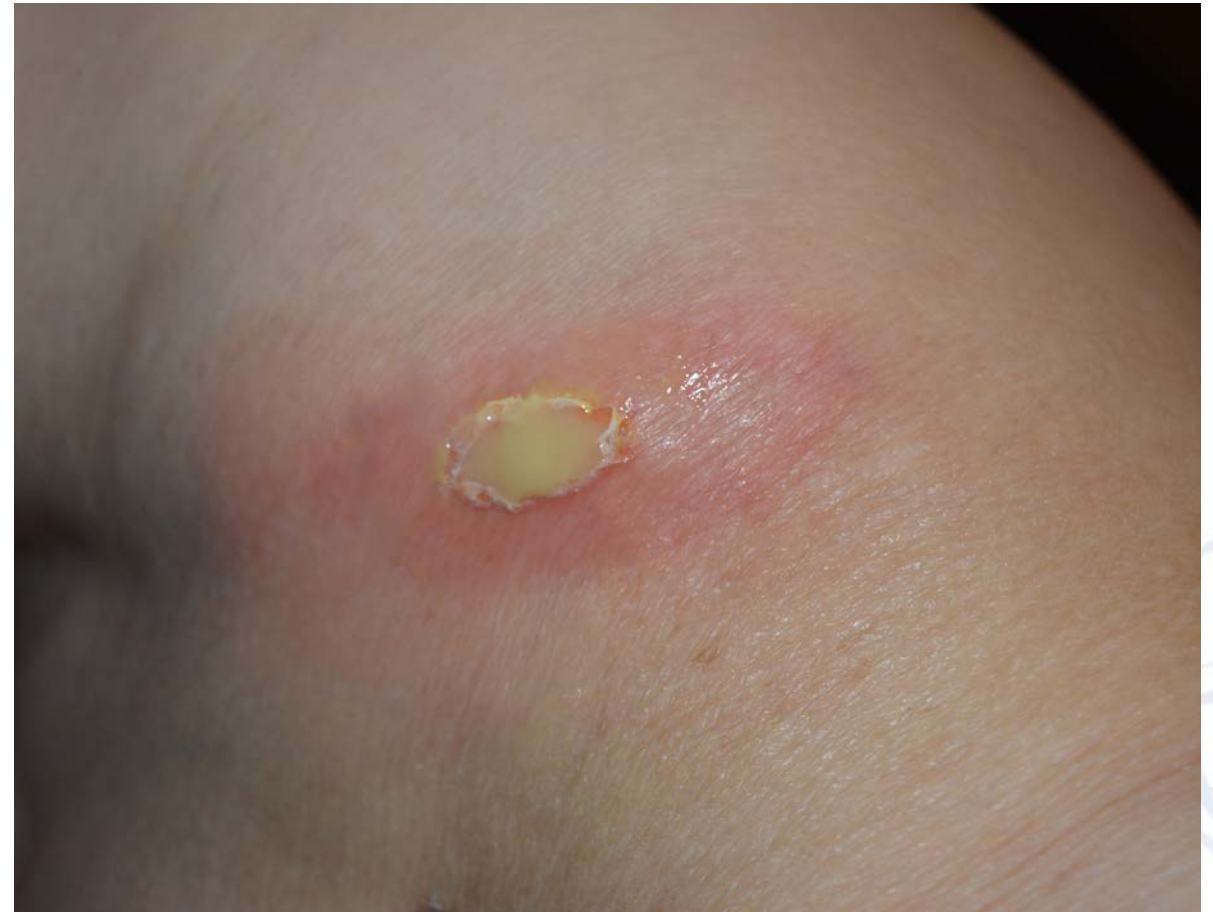Correct answer: suspected deep tissue injury

Explanation: the area of the wound is purple/maroon and the skin is intact. We can assume that the underlying soft tissue has been damaged.

# Question 14

What is this?

- Stage I pressure injury
- Stage II pressure injury
- Stage III pressure injury
- Stage IV pressure injury
- Unstageable pressure injury
- Suspected Deep Tissue Injury
- Moisture-associated skin damage



# Answer

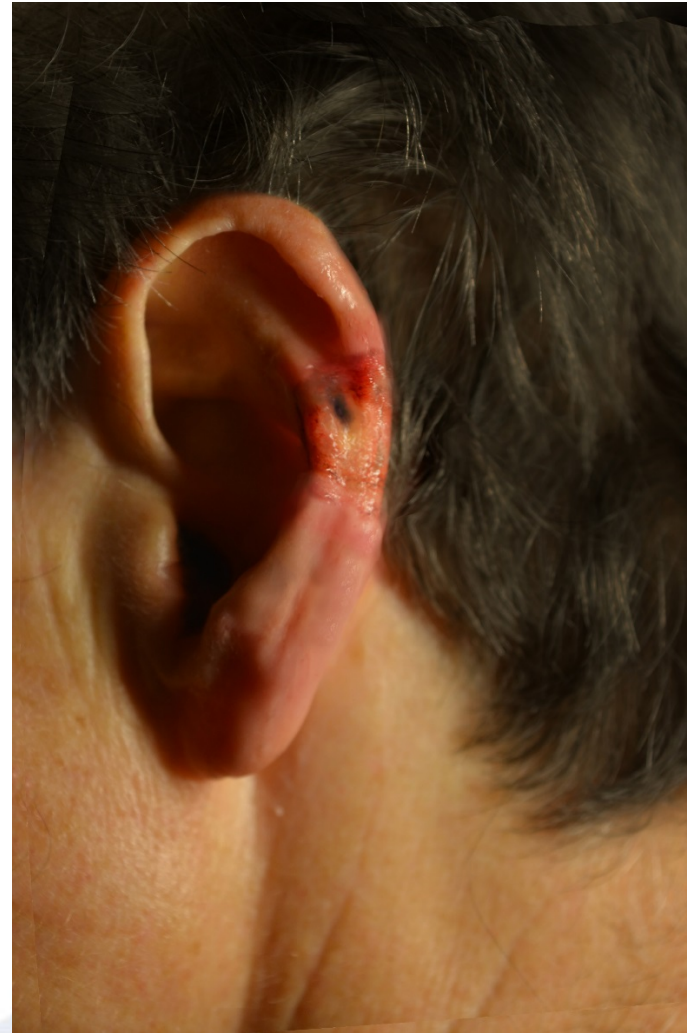Correct answer: Stage III pressure injury

Explanation: there is a full thickness tissue loss on the iliac crest with no exposition of the bone. Slough is excessively present.

# Question 15

What is this?

- Stage I pressure injury
- Stage II pressure injury
- Stage III pressure injury
- Stage IV pressure injury
- Unstageable pressure injury
- Suspected Deep Tissue Injury
- Moisture-associated skin damage



# Answer

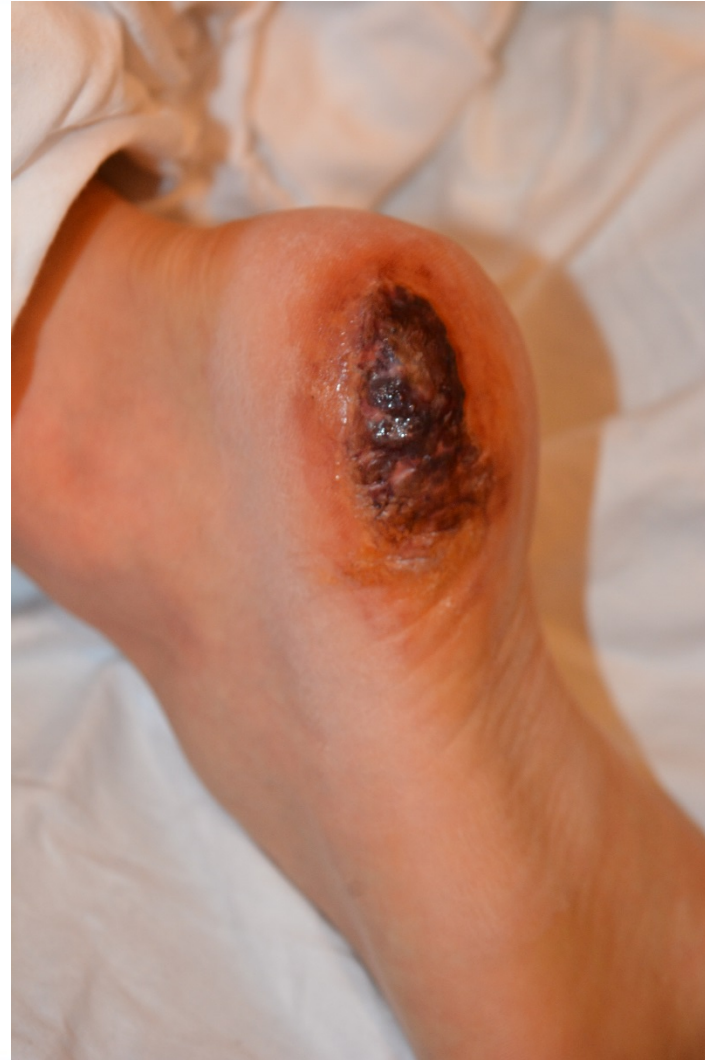Correct answer: Stage IV pressure injury

Explanation: the tissue damage indicates a stage IV pressure injury. The tissue loss is extensive and the cartilage of the ear is directly exposed.

# Question 16

What is this?

- Stage I pressure injury
- Stage II pressure injury
- Stage III pressure injury
- Stage IV pressure injury
- Unstageable pressure injury
- Suspected Deep Tissue Injury
- Moisture-associated skin damage



# Answer

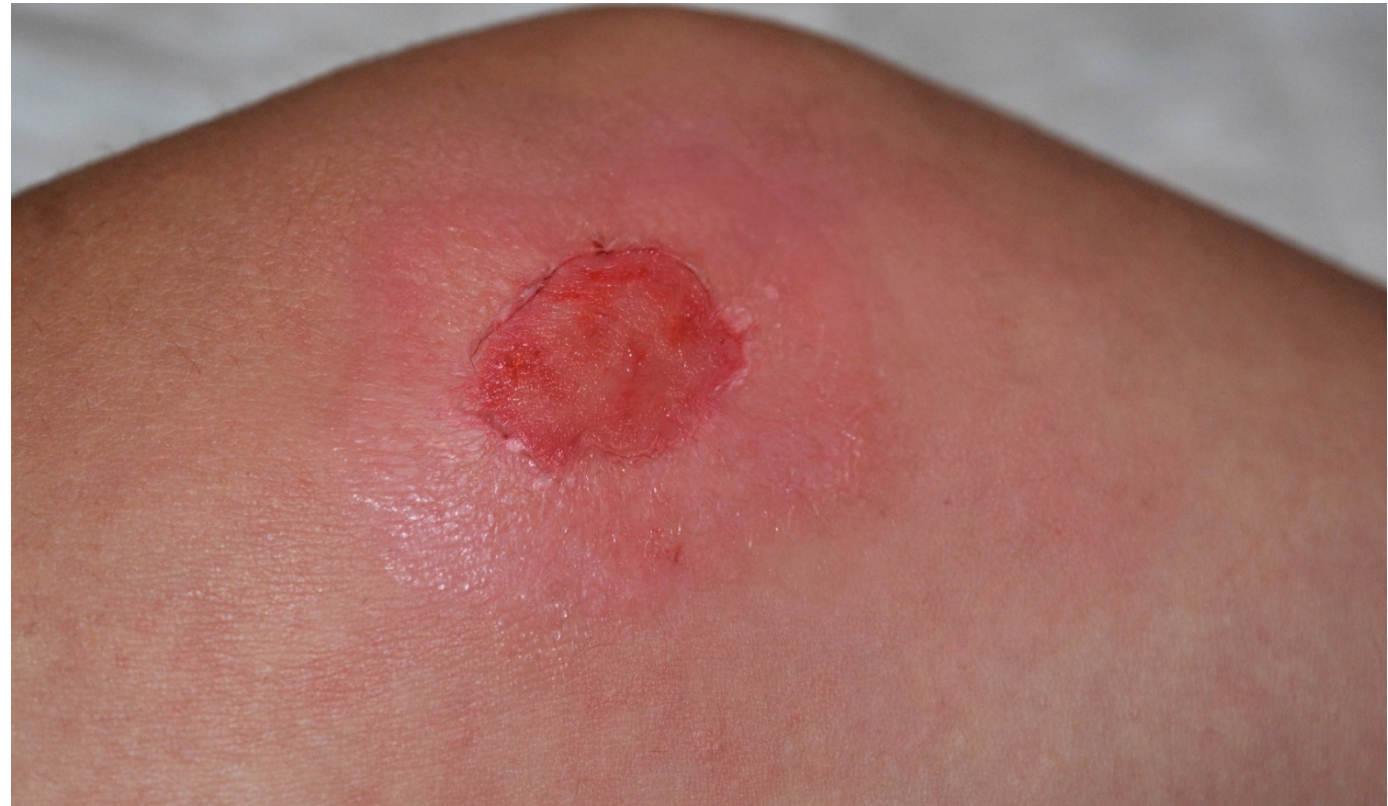Correct answer: unstageable pressure injury

Explanation: a dark eschar covers the localized wound area. The skin around the eschar is dark (maroon/brown). Until the eschar has been removed, the depth of the injury and the extent of the damage is not to be determined.

# Question 17

What is this?

- Stage I pressure injury
- Stage II pressure injury
- Stage III pressure injury
- Stage IV pressure injury
- Unstageable pressure injury
- Suspected Deep Tissue Injury
- Moisture-associated skin damage





# Answer

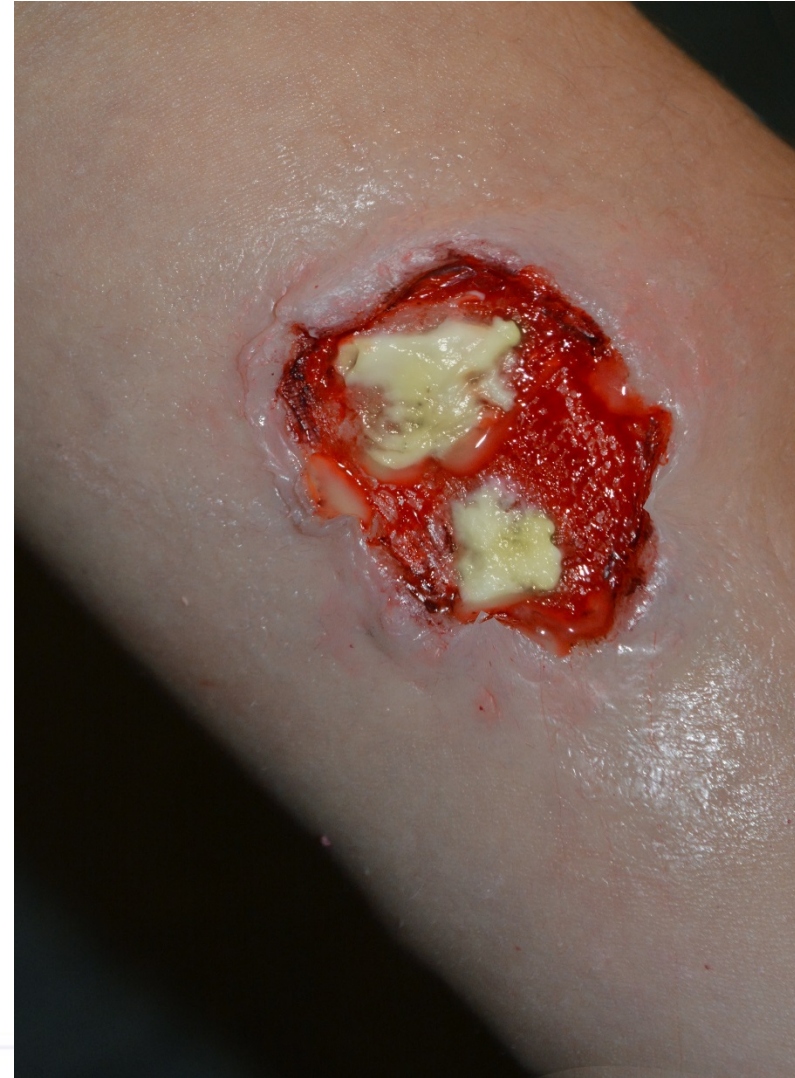Correct answer: Stage II pressure injury

Explanation: there is a clear partial thickness loss of dermis. The wound is presented as a dry, shallow open ulcer with a red/pink wound bed. There is no slough visible.

# Question 18

What is this?

- Stage I pressure injury
- Stage II pressure injury
- Stage III pressure injury
- Stage IV pressure injury
- Unstageable pressure injury
- Suspected Deep Tissue Injury
- Moisture-associated skin damage



# Answer

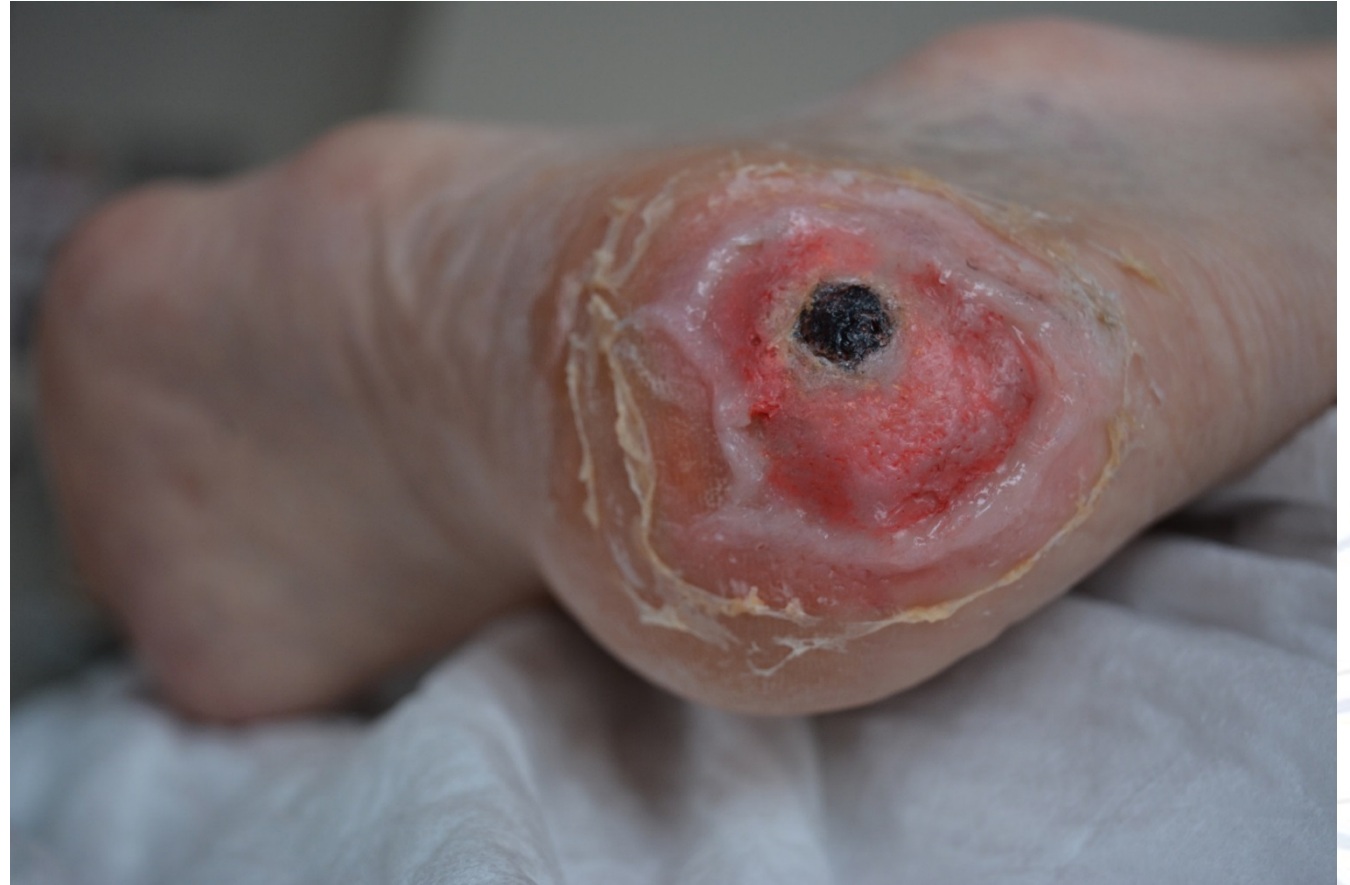Correct answer: Stage III pressure injury

Explanation: extensive full tissue loss with slough and eschar on some parts of the wound. The tissue might be undermined. The supporting tissues are probably invaded

# Question 19

What is this?

- Stage I pressure injury
- Stage II pressure injury
- Stage III pressure injury
- Stage IV pressure injury
- Unstageable pressure injury
- Suspected Deep Tissue Injury
- Moisture-associated skin damage



# Answer

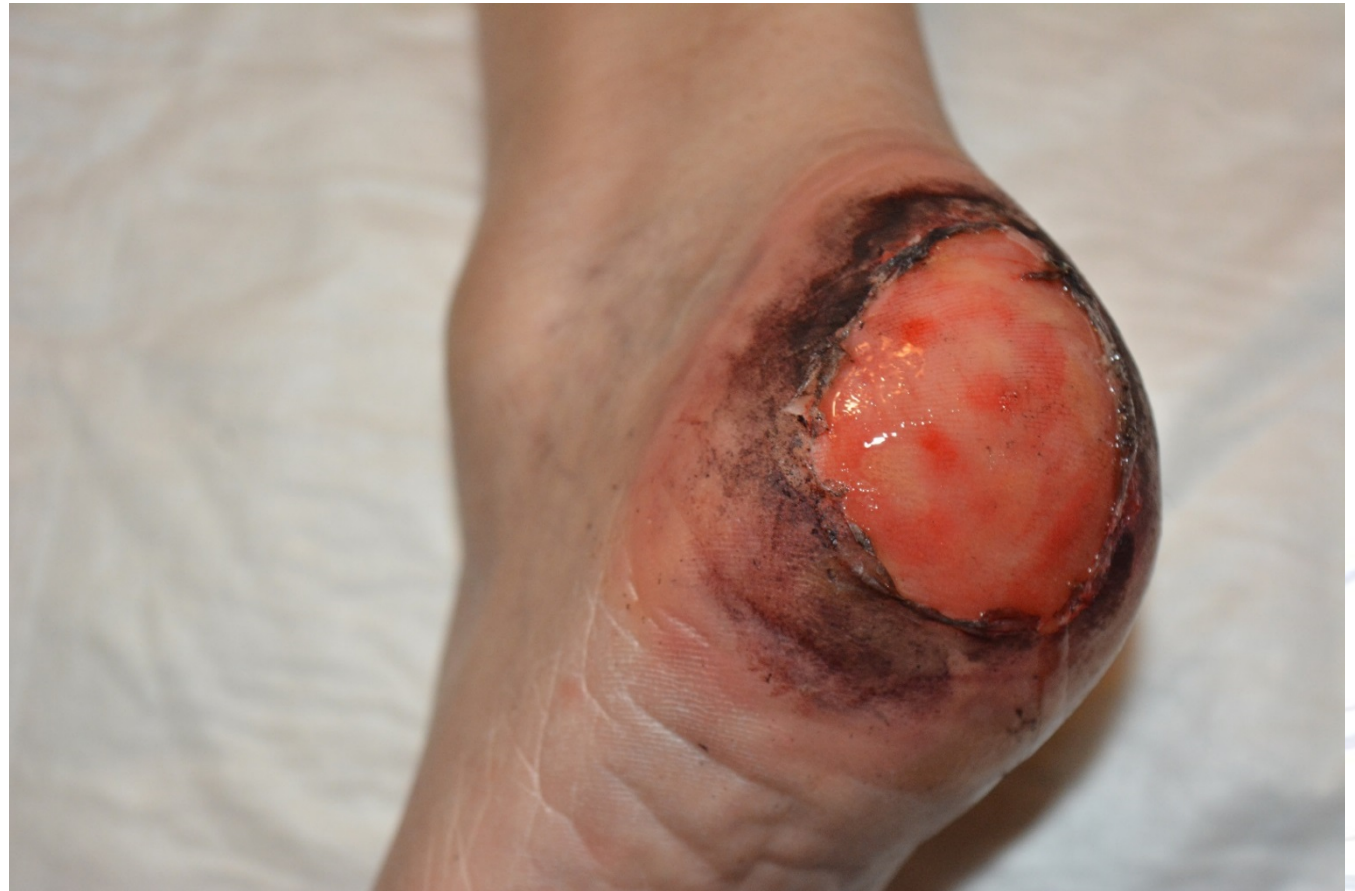Correct answer: Stage IV pressure injury

Explanation: there is a full thickness tissue loss with exposed bone.

# Question 20

What is this?

- Stage I pressure injury
- Stage II pressure injury
- Stage III pressure injury
- Stage IV pressure injury
- Unstageable pressure injury
- Suspected Deep Tissue Injury
- Moisture-associated skin damage



# Answer

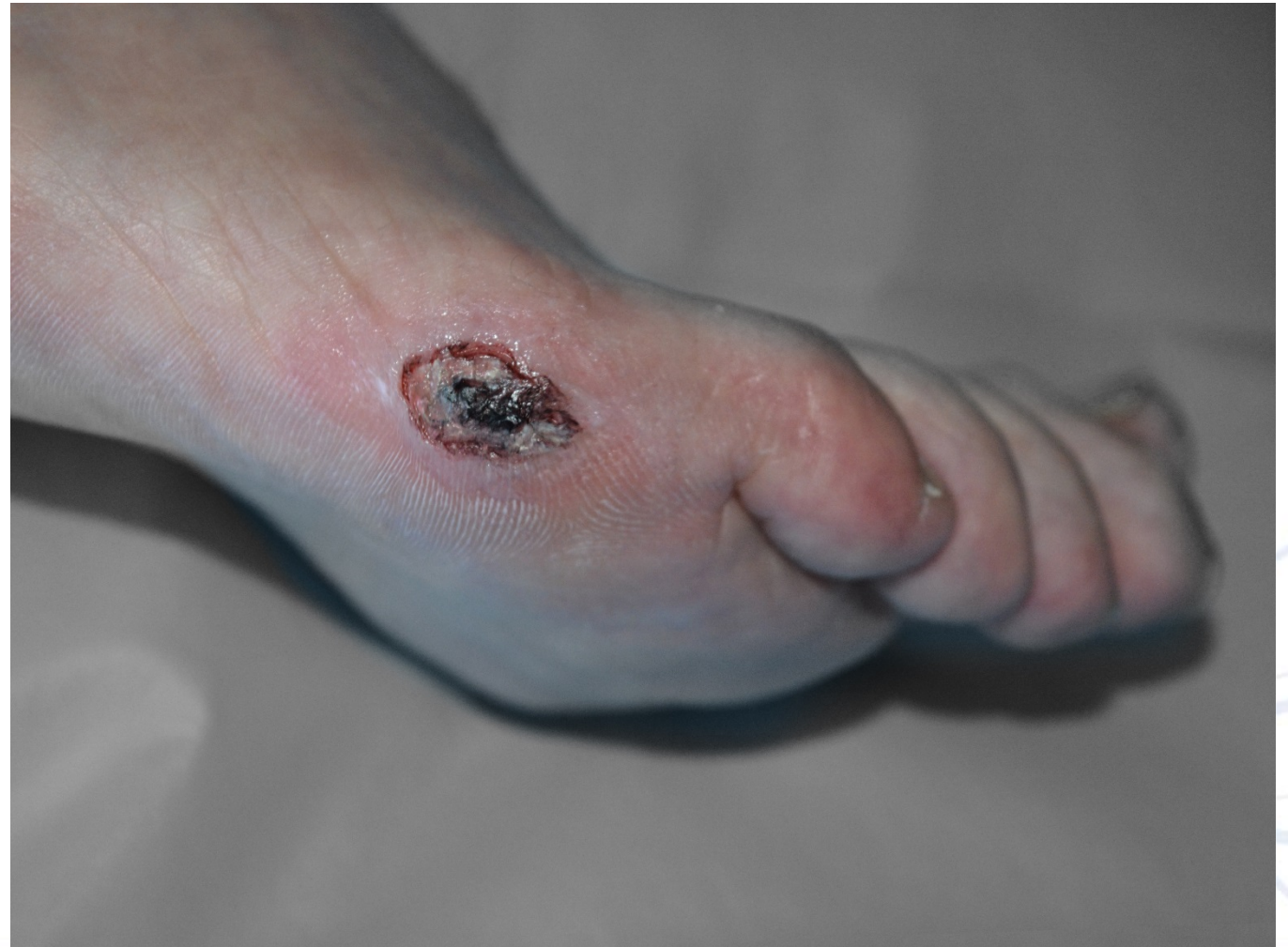Correct answer: Stage II pressure injury

Explanation: there is an explicit partial thickness skin loss on the heel. The injury is presented as an open blister with a red pink wound bed. There is no slough detectable.

# Question 21

What is this?

- Stage I pressure injury
- Stage II pressure injury
- Stage III pressure injury
- Stage IV pressure injury
- Unstageable pressure injury
- Suspected Deep Tissue Injury
- Moisture-associated skin damage





# Answer

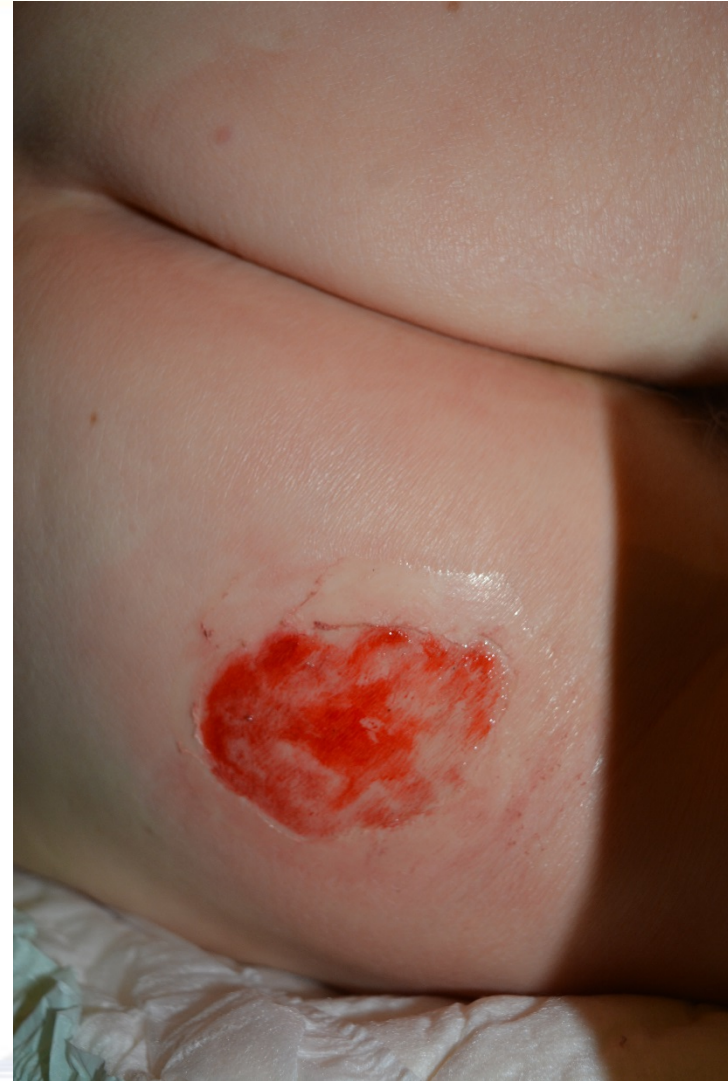Correct answer: Stage IV pressure injury

Explanation: Stage IV pressure injury is characterised by full thickness tissue loss. The tissue loss is extensive. Removing the necrotic eschar would expose the underlying bone. There is a risk of osteomyelitis.

# Question 22

What is this?

- Stage I pressure injury
- Stage II pressure injury
- Stage III pressure injury
- Stage IV pressure injury
- Unstageable pressure injury
- Suspected Deep Tissue Injury
- Moisture-associated skin damage



# Answer

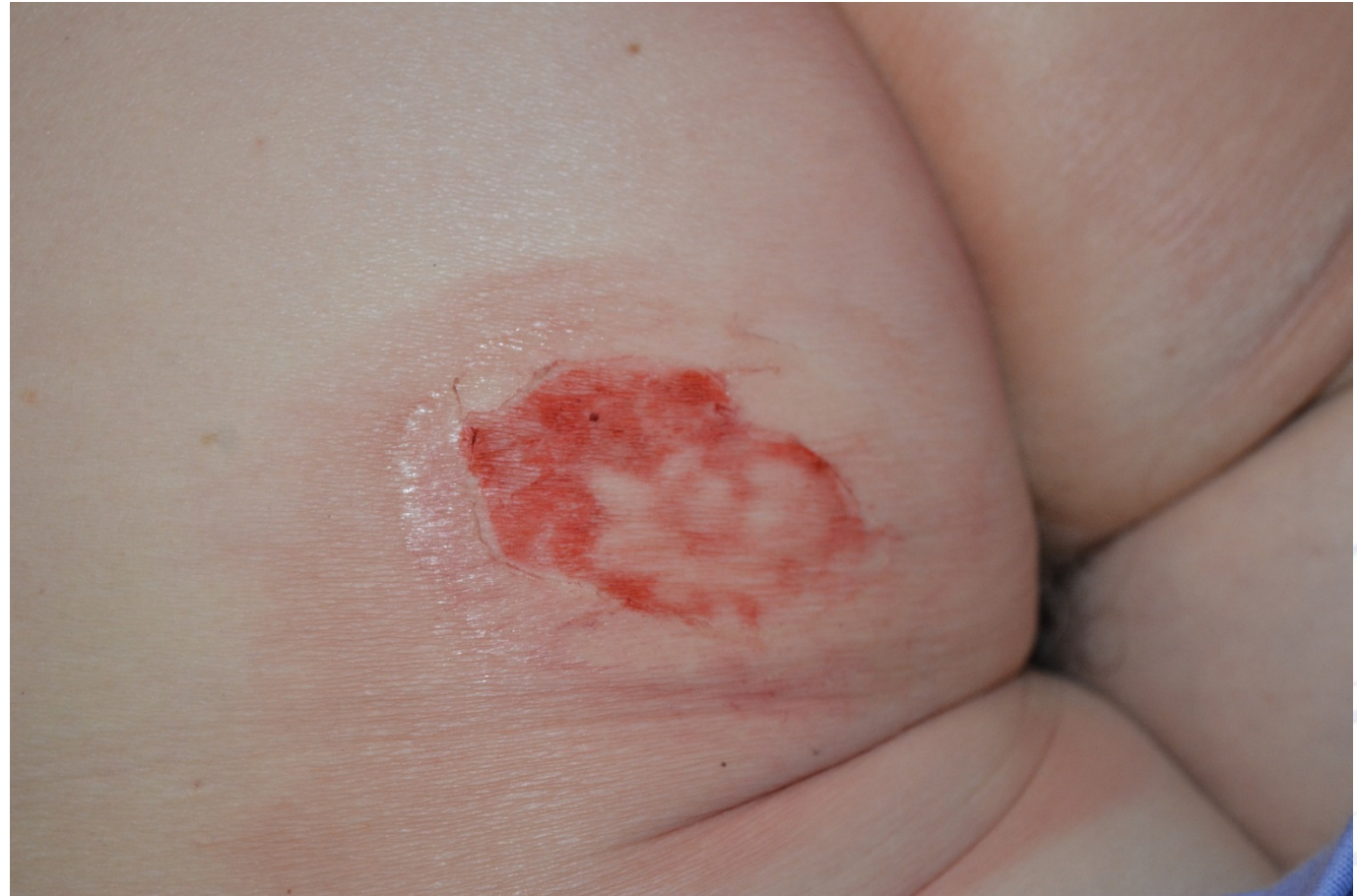Correct answer: Stage II pressure injury

Explanation: the wound is presented as a partial thickness skin loss of the gluteal region. The injury is superficial. The blister is open and the wound bed red. There is no slough detectable.

# Question 23

What is this?

- Stage I pressure injury
- Stage II pressure injury
- Stage III pressure injury
- Stage IV pressure injury
- Unstageable pressure injury
- Suspected Deep Tissue Injury
- Moisture-associated skin damage



# Answer

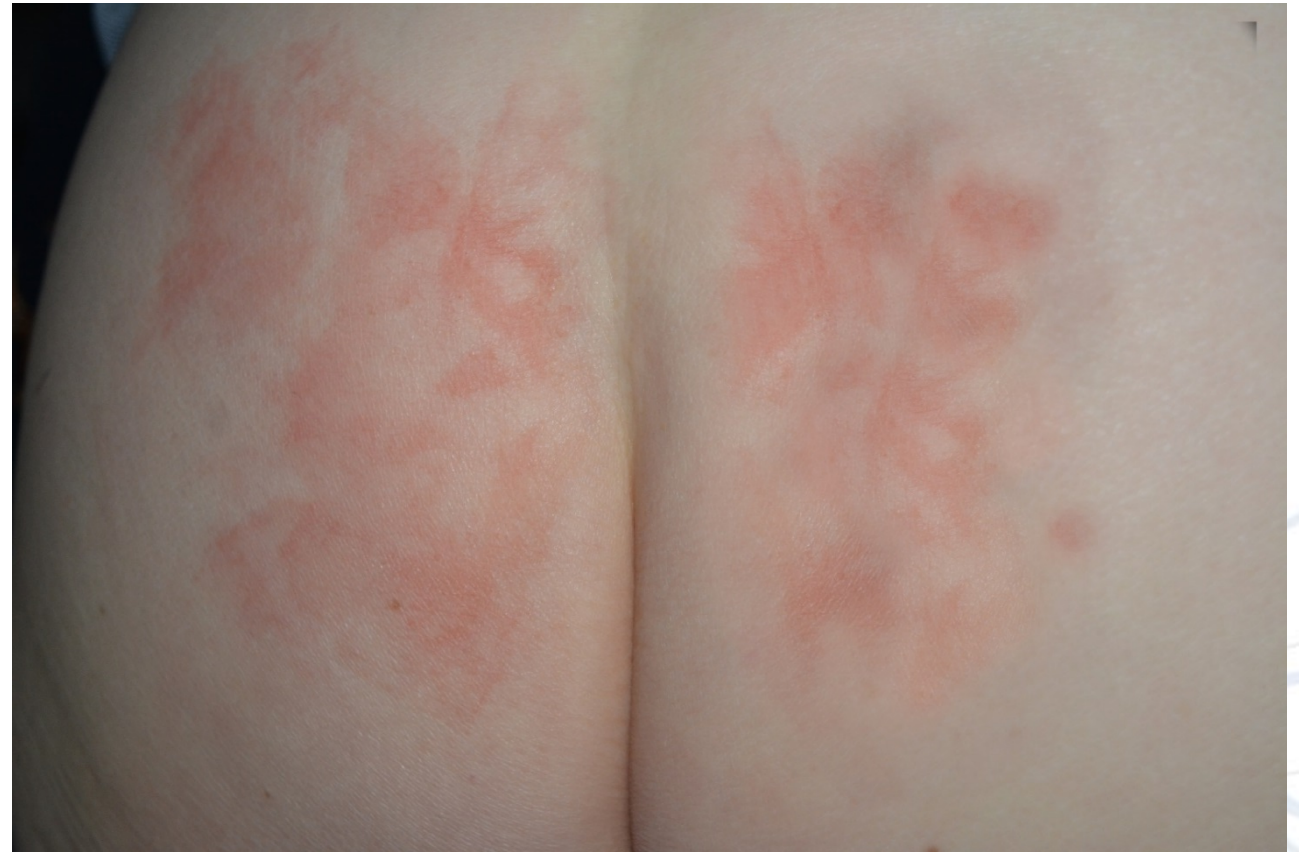Correct answer: Stage II pressure injury

Explanation: there is a clear partial thickness loss of dermis. The wound is presented as a shallow open ulcer with a red/pink wound bed. There is no slough visible.

# Question 24

What is this?

- Stage I pressure injury
- Stage II pressure injury
- Stage III pressure injury
- Stage IV pressure injury
- Unstageable pressure injury
- Suspected Deep Tissue Injury
- Moisture-associated skin damage



# Answer

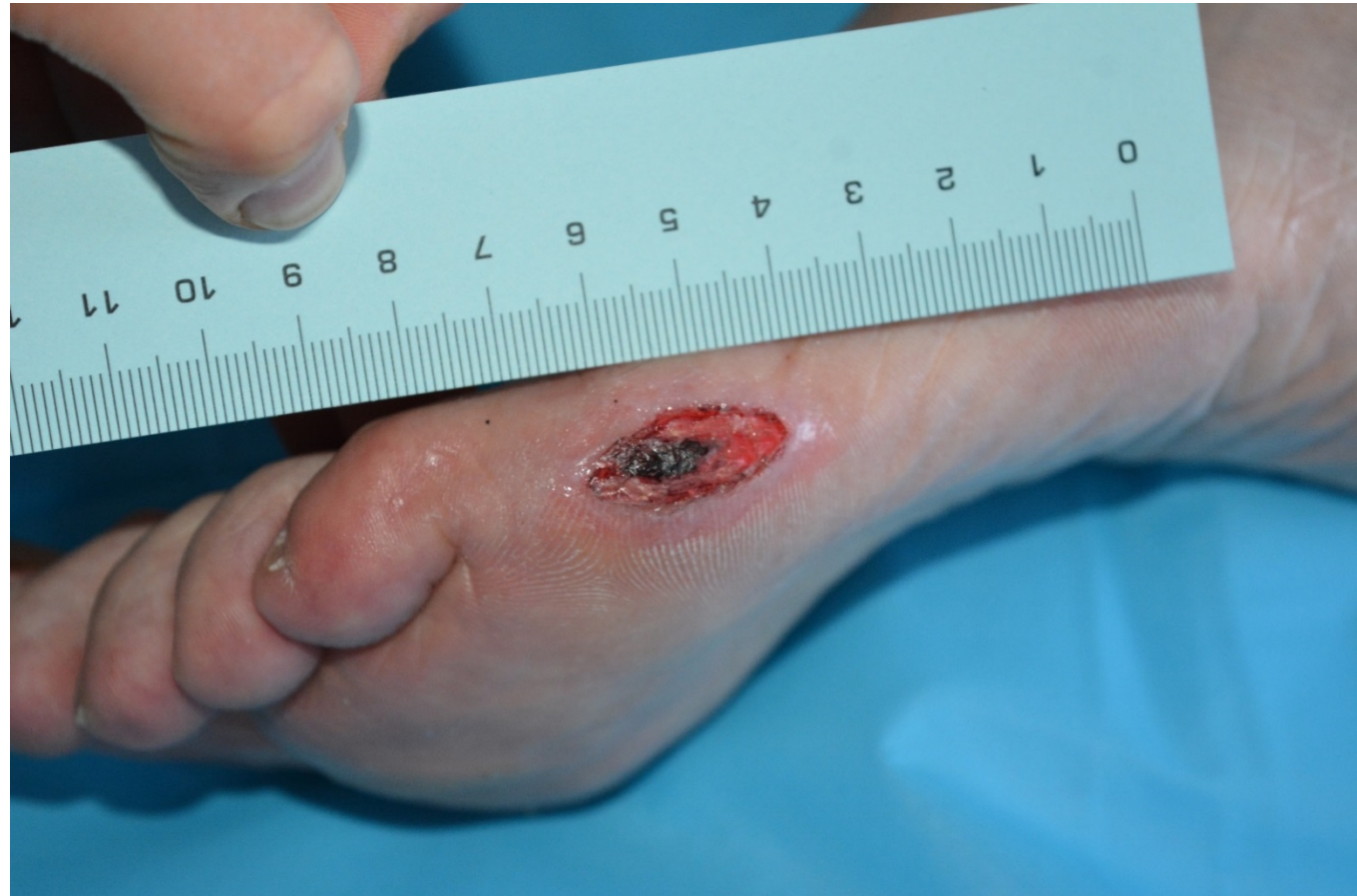Correct answer: moisture-associated skin damage (MASD), possibly incontinence-related.

Explanation: there is a noticeable erythema of the skin. The skin redness is diffuse. The inflammation of the skin is caused by exposure to moisture.

# Question 25

What is this?

- Stage I pressure injury
- Stage II pressure injury
- Stage III pressure injury
- Stage IV pressure injury
- Unstageable pressure injury
- Suspected Deep Tissue Injury
- Moisture-associated skin damage





# Answer

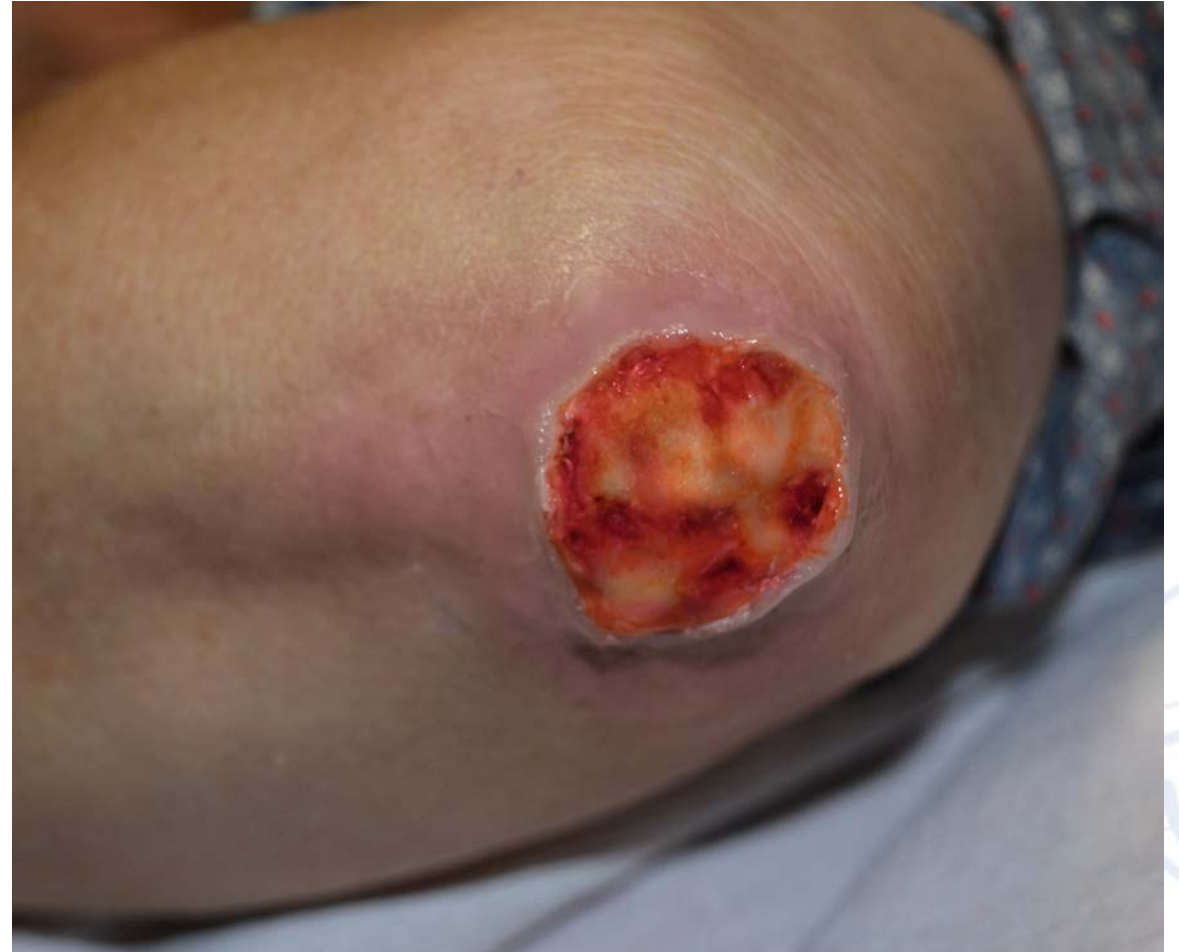Correct answer: Stage IV pressure injury

Explanation: Stage IV pressure injury is characterised by full thickness tissue loss. The tissue loss is extensive. Removing the necrotic eschar would expose the underlying bone. There is a risk of osteomyelitis.

# Question 26

What is this?

- Stage I pressure injury
- Stage II pressure injury
- Stage III pressure injury
- Stage IV pressure injury
- Unstageable pressure injury
- Suspected Deep Tissue Injury
- Moisture-associated skin damage



# Answer

Correct answer: Stage IV pressure injury

Explanation: The tissue loss is extensive, and the underlying bone is exposed. There is a risk of osteomyelitis.

Congratulations, you have finished the e-learning module.

Thank you for your time.

We hope that we have fulfilled your expectations and that this module will help you to correctly classify pressure injuries.



# Authorship

This module was developed by Marta BORKOWSKA<sup>1</sup>, Vincianne PLEITINCKX<sup>2</sup>, Liesbet DEMARRE<sup>3</sup>, Mireia LLAURADO-SERRA<sup>4</sup>, Stijn BLOT<sup>5</sup> and Sonia LABEAU<sup>6</sup> .

<sup>1</sup> Ghent University Hospital, Ghent, Belgium

<sup>2</sup> Arjo Belgium

<sup>3</sup> General Hospital Sint-Elizabeth, Zottegem, Belgium

<sup>4</sup> Universitat Internacional de Catalunya, Barcelona, Spain

<sup>5</sup> Ghent University, Ghent, Belgium

<sup>6</sup> Ghent University and Ghent University College, Ghent, Belgium



# Disclaimer and acknowledgements

By using this course you agree with the content of this disclaimer.

The wounds presented in this e-learning module are simulations, based on representations of true skin lesions. They are shown on healthy adults, who voluntarily participate in this project after written informed consent.

We gratefully acknowledge Ms. Ellen Devos, (Bodypaint by Ellen), for the skillful simulations, and the volunteers represented on the photographs for their appreciated collaboration. We are also grateful to The Life Priority Fund of the European Society for Intensive Care Medicine and the Flemish Society for Critical Care Nurses for funding this project.

Although we aim to provide information that is up-to-date and correct, we are not able to guarantee the result. We reserve the right to change the course at any time at our sole discretion.

We disclaim responsibility for all direct or indirect damages that may result from the access or use of this course, or for damages or a virus that might cause harm to your computer or accessories.

Certain information in this course may refer to or link information originating from other organisations. The societies, organisations, and internet sites presented on this site have been chosen, with the sole aim to provide the most relevant information to the visitors of our site. We do nevertheless not guarantee the relevance, updating or correctness of this external information and disclaim every responsibility.

This e-learning module was specifically designed to support the DecubICUs study. The module, and the information which it contains, is the property of Stijn Blot and is protected from unauthorized copying and dissemination by Belgian laws and international treaties regarding copyright and intellectual property. Any use of the content not expressly permitted may violate copyright laws. It is strictly prohibited to use this module and its contents for any other purpose than DecubICUs, or to share any of its items with any third party.



[Start e-learning module](#)

[www.esicm.org](http://www.esicm.org)