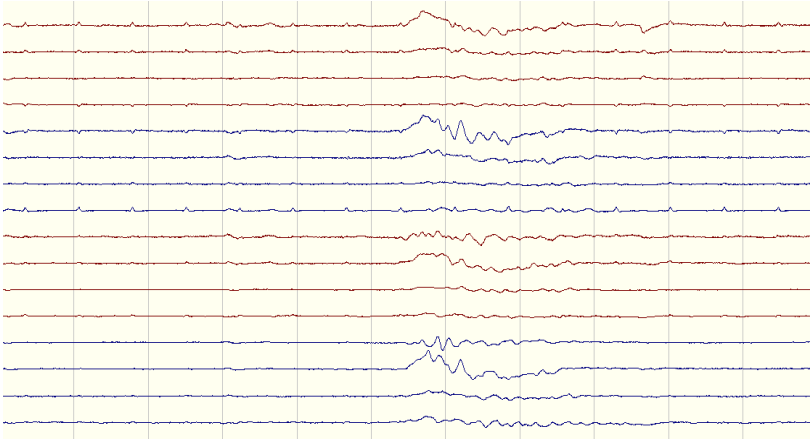
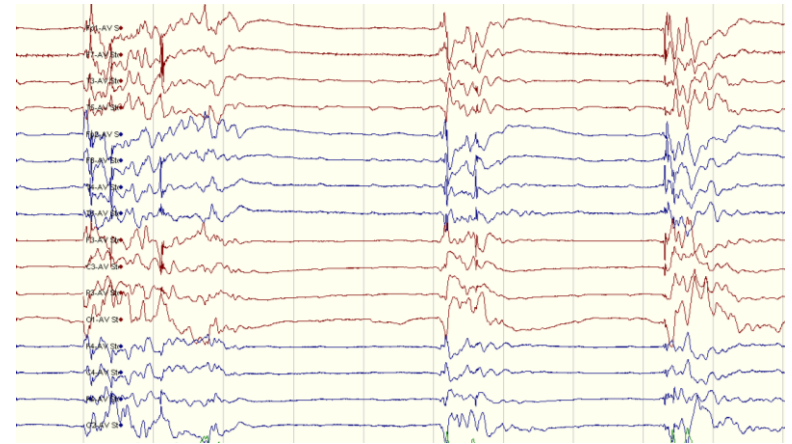


ESM Figure E1 – Highly malignant EEG patterns

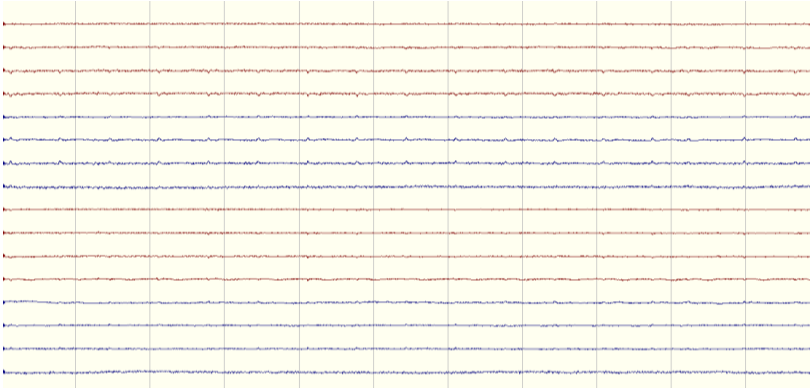
Burst-suppression without discharges



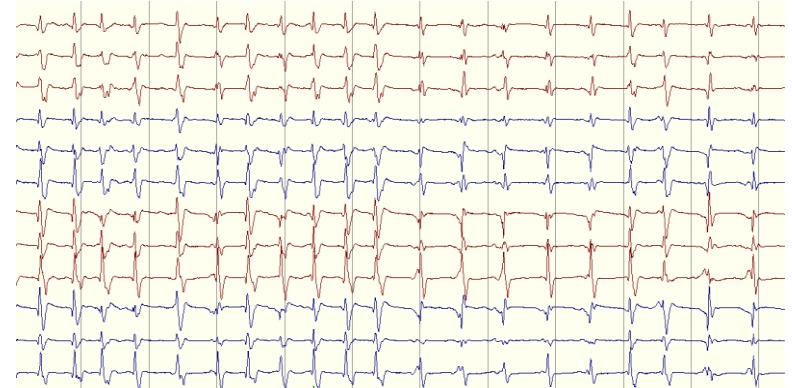
Burst-suppression with discharges



Suppression without discharges



Suppression with discharges



Highly malignant patterns defined using the standardized EEG terminology by the American Clinical Neurophysiology Society:
Burst-suppression (amplitude $<10\mu\text{V}$, $\geq 50\%$ of the recording) without discharges; Burst-suppression with discharges;
Suppressed background (amplitude $<10\mu\text{V}$ the entirety of the record) without discharges; Suppressed background with periodic discharges.