

Supplementary Material

Tapinarof Cream 1% Once Daily for the Treatment of Plaque Psoriasis: Case Photography of Clinical Outcomes from Three Phase 3 Trials

Seemal R. Desai,^{1,2} Linda Stein Gold,³ Michael C. Cameron,^{4,5} Alexandra Golant,⁵ G. Michael Lewitt,⁶ Matthew J. Bruno,⁷ George Martin,⁸ Philip M. Brown,⁹ David S. Rubenstein,⁹ Victoria Butners,⁹ Anna M. Tallman⁹

Affiliations:

¹Department of Dermatology, The University of Texas Southwestern Medical Center, Dallas, TX, USA;

²Innovative Dermatology, Plano, TX, USA;

³Henry Ford Health System, Detroit, MI, USA;

⁴Cameron Dermatology, New York, NY, USA

⁵Icahn School of Medicine at Mount Sinai, New York, NY, USA;

⁶Illinois Dermatology Institute, Chicago, IL, USA;

⁷Dermatology & Skin Cancer Surgery Center, Allen, TX, USA;

⁸George Martin Dermatology Associates, Kihei, HI, USA;

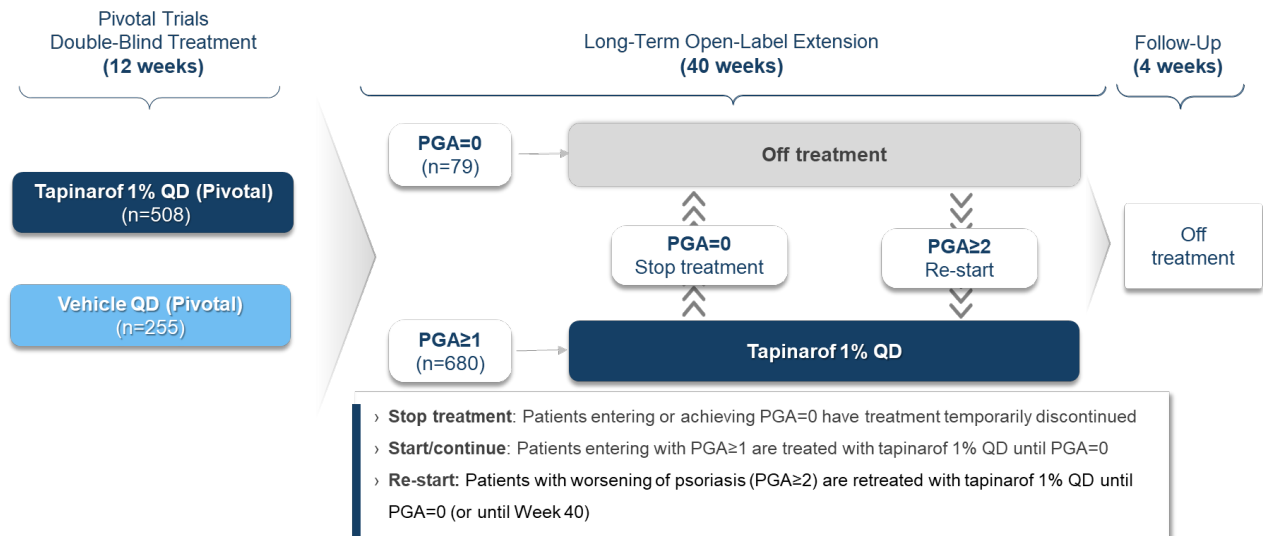
⁹Dermavant Sciences, Inc., Morrisville, NC, USA

Author for correspondence:

Seemal R. Desai, MD, FAAD

seemald@yahoo.com

Supplementary Figure S1. PSOARING 3 Trial Design



PGA, Physician Global Assessment; QD, once daily.