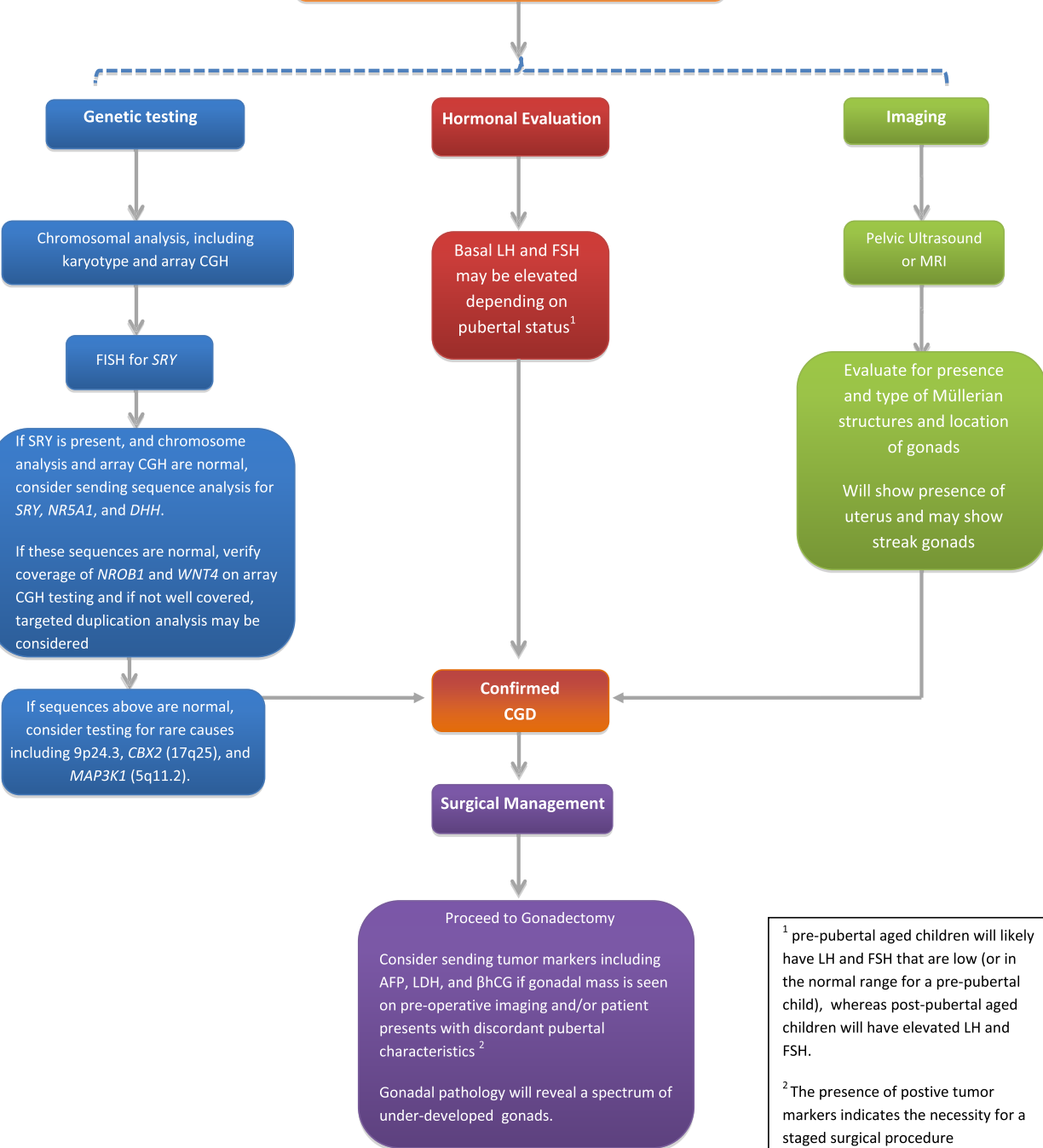


Patients with suspected 46,XY CGD based on history and physical exam



¹ pre-pubertal aged children will likely have LH and FSH that are low (or in the normal range for a pre-pubertal child), whereas post-pubertal aged children will have elevated LH and FSH.

² The presence of positive tumor markers indicates the necessity for a staged surgical procedure (laparotomy instead of laparoscopy).