

## SUPPLEMENTARY MATERIAL

### **Anti-N-methyl-D-aspartate receptor encephalitis in People living with HIV: case report and literature review**

Jiangjin Hui<sup>†</sup>, Qing Cao<sup>1†</sup>, Zhikai Wan<sup>1†</sup>, Bohao Dai<sup>1</sup>, Haiyan Lou<sup>2</sup>, Biao Zhu<sup>1</sup>

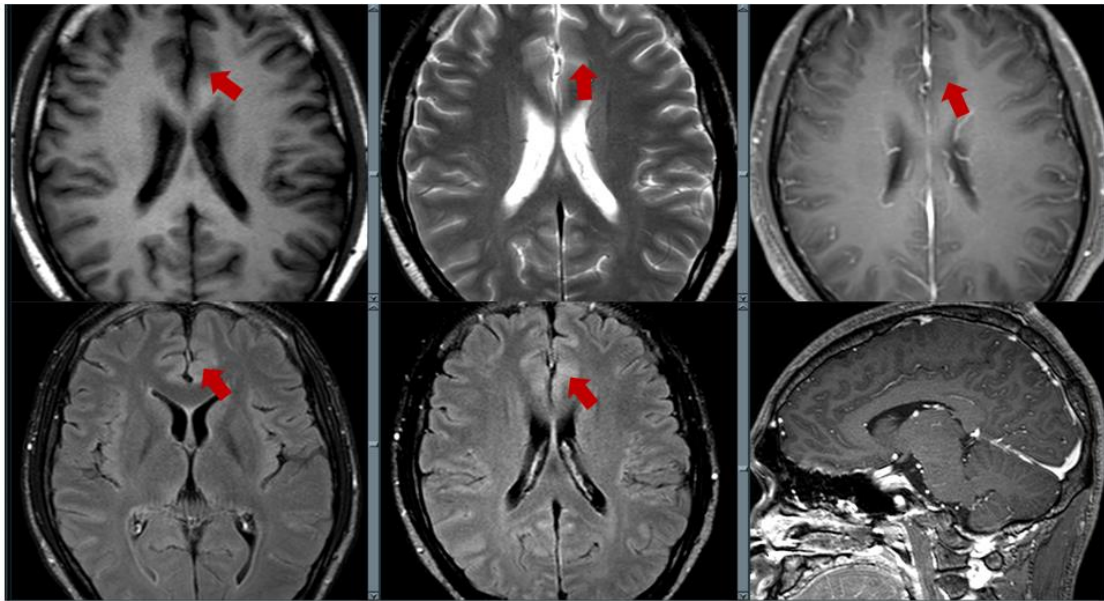
1. Department of Infectious Diseases, State Key Laboratory for Diagnosis and Treatment of Infectious Diseases, Collaborative Innovation Center for Diagnosis and Treatment of Infectious Diseases, National Clinical Research Center for Infectious Diseases, the First Affiliated Hospital, Zhejiang University School of Medicine, Hangzhou 310006, China

2. Radiology Department, the First Affiliated Hospital, Zhejiang University School of Medicine, Hangzhou 310006, China

**Correspondence:** Zhu Biao, Tel.: 13906535457; E-mail address: [zhubiao1207@zju.edu.cn](mailto:zhubiao1207@zju.edu.cn);  
<https://orcid.org/0000-0001-6288-4575>

<sup>†</sup>These authors contributed equally to this work and share first authorship.

Figure S1 Cerebral magnetic resonance imaging



Transverse magnetic resonance imaging (MRI) showing slight swelling of the left frontal cortex, long T1 low-signal and long T2 hypersignal lesions, no enhancement on enhanced scanning, and abnormal signals in the left frontal cortex on T2-weighted FLAIR imaging (arrowheads). FLAIR: fluid-attenuated inversion recovery.

## References:

1. Graus F, Titulaer MJ, Balu R, Benseler S, Bien CG, Cellucci T, et al. A clinical approach to diagnosis of autoimmune encephalitis. *The Lancet Neurology*. 2016;15(4):391-404.
2. Patarata E, Bernardino V, Martins A, Pereira R, Loureiro C, Moraes-Fontes MF. Anti-N-Methyl-D-Aspartate Receptor Encephalitis in HIV Infection. *Case reports in neurology*. 2016;8(3):251-7.
3. Haneche F, Demeret S, Psimaras D, Katlama C, Pourcher V. An anti-NMDA receptor encephalitis mimicking an HIV encephalitis. *Clinical immunology (Orlando, Fla)*. 2018;193:10-1.
4. Granerod J, Ambrose HE, Davies NW, Clewley JP, Walsh AL, Morgan D, et al. Causes of encephalitis and differences in their clinical presentations in England: a multicentre, population-based prospective study. *The Lancet Infectious diseases*. 2010;10(12):835-44.
5. Moloney PB, Hutchinson S, Heskin J, Mulcahy F, Langan Y, Conlon NP, et al. Possible N-methyl-D-aspartate receptor antibody-mediated encephalitis in the setting of HIV cerebrospinal fluid escape. *Journal of neurology*. 2020;267(5):1348-52.
6. Schäbitz WR, Rogalewski A, Hagemeister C, Bien CG. VZV brainstem encephalitis triggers NMDA receptor immunoreaction. *Neurology*. 2014;83(24):2309-11.
7. Ioannidis P, Papadopoulos G, Koufou E, Parisis D, Karacostas D. Anti-NMDA receptor encephalitis possibly triggered by measles virus. *Acta neurologica Belgica*. 2015;115(4):801-2.
8. Dutra LA, Abrantes F, Toso FF, Pedrosa JL, Barsottini OGP, Hoftberger R. Autoimmune encephalitis: a review of diagnosis and treatment. *Arquivos de neuro-psiquiatria*. 2018;76(1):41-9.
9. Nosadini M, Eyre M, Molteni E, Thomas T, Irani SR, Dalmau J, et al. Use and Safety of Immunotherapeutic Management of N-Methyl-d-Aspartate Receptor Antibody Encephalitis: A Meta-analysis. *JAMA neurology*. 2021;78(11):1333-44.
10. Chinese Society of Neuroinfectious Diseases and Cerebrospinal Fluid Cytology. Chinese expert consensus on the diagnosis and management of autoimmune encephalitis (2022 edition) *Chinese Journal of Neurology*. 2022;55(9):931-49.
11. Arboleya S, Clemente A, Deng S, Bedmar M, Salvador I, Herbera P, et al. Anti-NMDAR antibodies in new-onset psychosis. Positive results in an HIV-infected patient. *Brain, behavior, and immunity*. 2016;56:56-60.
12. Anguizola-Tamayo D, Bocos-Portillo J, Pardina-Vilella L, Rodriguez-Sainz A, Vicente-Olabarria I, Martínez E, et al. Psychosis of dual origin in HIV infection: Viral escape syndrome and autoimmune encephalitis. *Neurology Clinical practice*. 2019;9(2):178-80.
13. Pinzon-Charry A, Wallace G, Clark JE, Nourse C. Anti-NMDA-receptor Encephalitis in an Adolescent With HIV Infection and Review of the Literature. *The Pediatric infectious disease journal*. 2019;38(8):e169-e71.
14. Cunill V, Arboleya S, Jiménez ML, Campins A, Herbera P, Mestre L, et al. Neuronal surface antibodies in HIV-infected patients with isolated psychosis. *Journal of neuroimmunology*. 2016;301:49-52.
15. Gresa-Arribas N, Titulaer MJ, Torrents A, Aguilar E, McCracken L, Leypoldt F, et al. Antibody titres at diagnosis and during follow-up of anti-NMDA receptor encephalitis: a retrospective study. *The Lancet Neurology*. 2014;13(2):167-77.
16. Louboutin JP, Strayer DS. Blood-brain barrier abnormalities caused by HIV-1 gp120: mechanistic

and therapeutic implications. *TheScientificWorldJournal*. 2012;2012:482575.

17. King JE, Eugenin EA, Hazleton JE, Morgello S, Berman JW. Mechanisms of HIV-tat-induced phosphorylation of N-methyl-D-aspartate receptor subunit 2A in human primary neurons: implications for neuroAIDS pathogenesis. *The American journal of pathology*. 2010;176(6):2819-30.

18. Byun JI, Lee ST, Moon J, Jung KH, Sunwoo JS, Lim JA, et al. Distinct intrathecal interleukin-17/interleukin-6 activation in anti-N-methyl-d-aspartate receptor encephalitis. *Journal of neuroimmunology*. 2016;297:141-7.

19. Damba JJ, Laskine M, Peet MM, Jin Y, Sinyavskaya L, Durand M. Corticosteroids Use and Incidence of Severe Infections in People Living with HIV Compared to a Matched Population. *Journal of the International Association of Providers of AIDS Care*. 2022;21:23259582221107196.