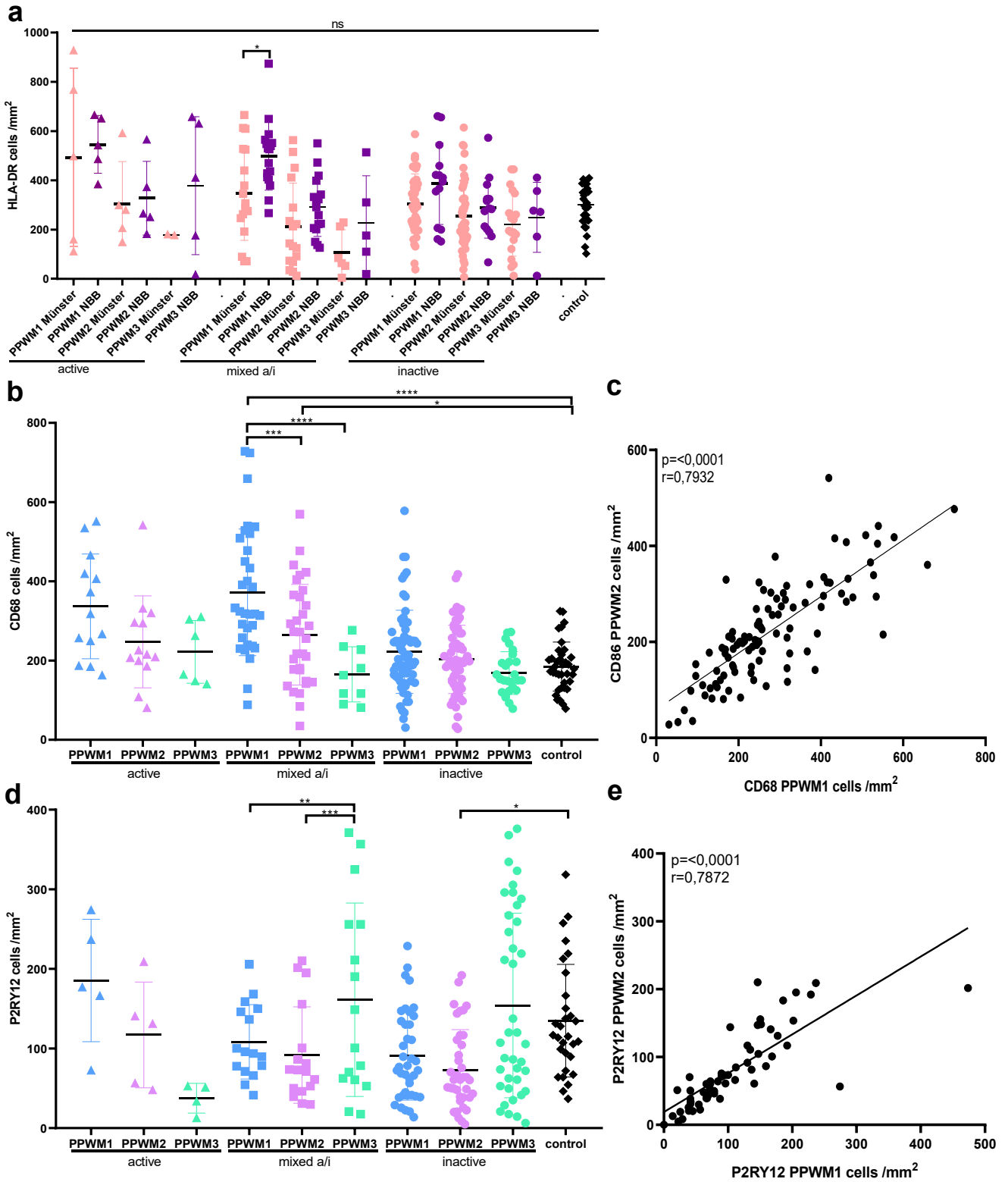
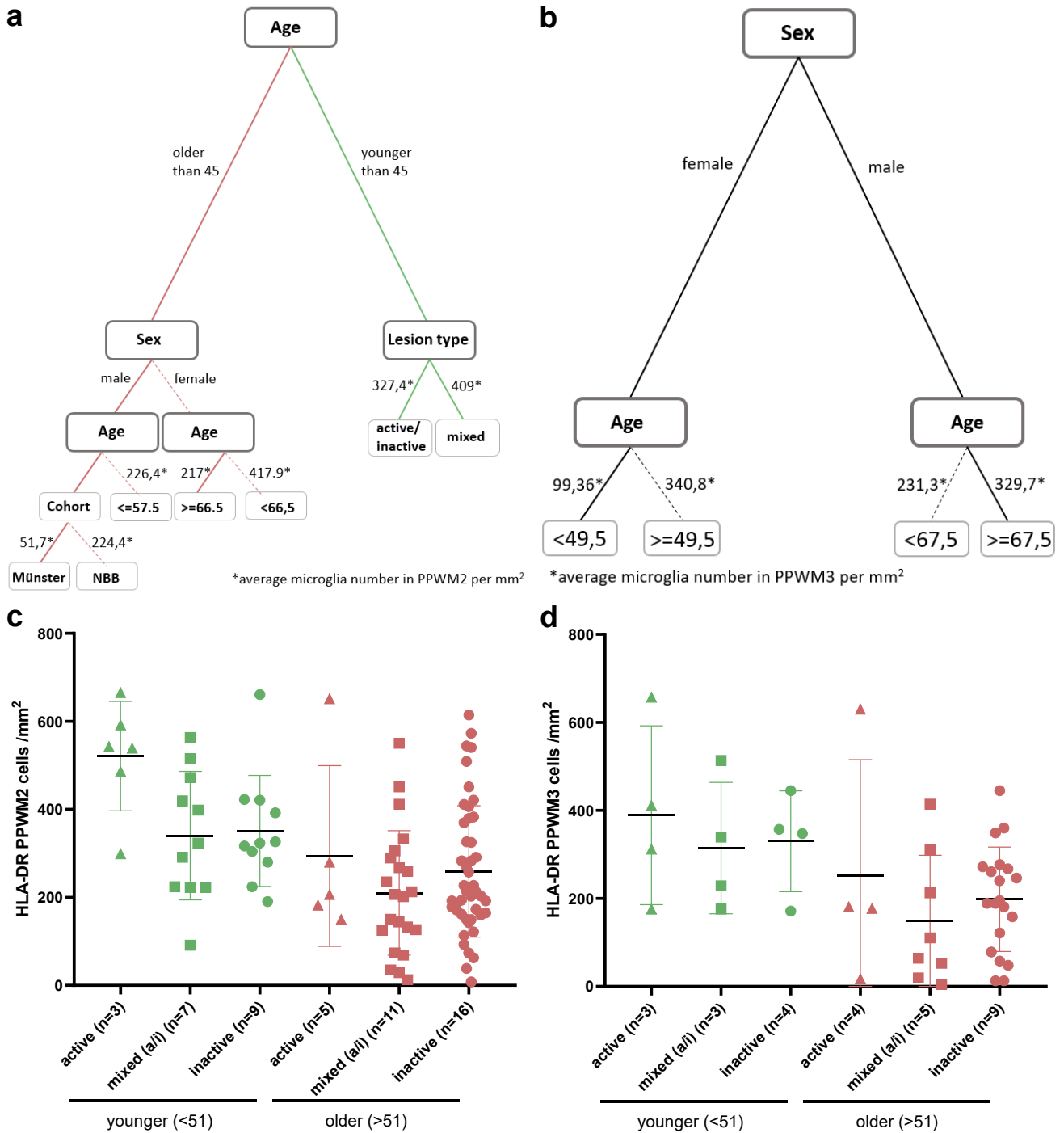


Supplementary Figure 1



Microglia activation in periplaque white matter in multiple sclerosis depends on age and lesion type, but does not correlate with oligodendroglial loss, *Acta Neuropathologica*, Wiebke Kessler, tanja.kuhlmann@ukmuenster.de

Supplementary Figure 2



Microglia activation in periplaque white matter in multiple sclerosis depends on age and lesion type, but does not correlate with oligodendroglial loss, *Acta Neuropathologica*, Wiebke Kessler, tanja.kuhlmann@ukmuenster.de