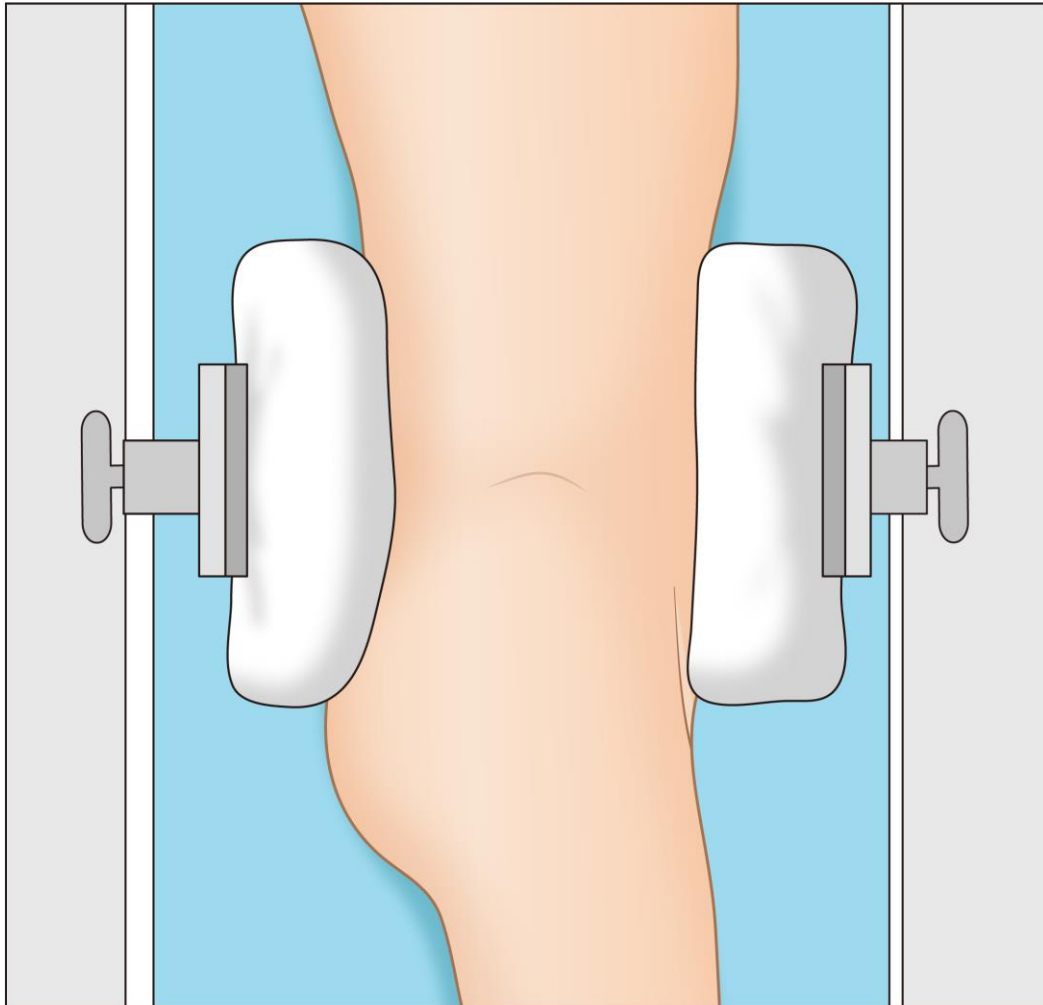
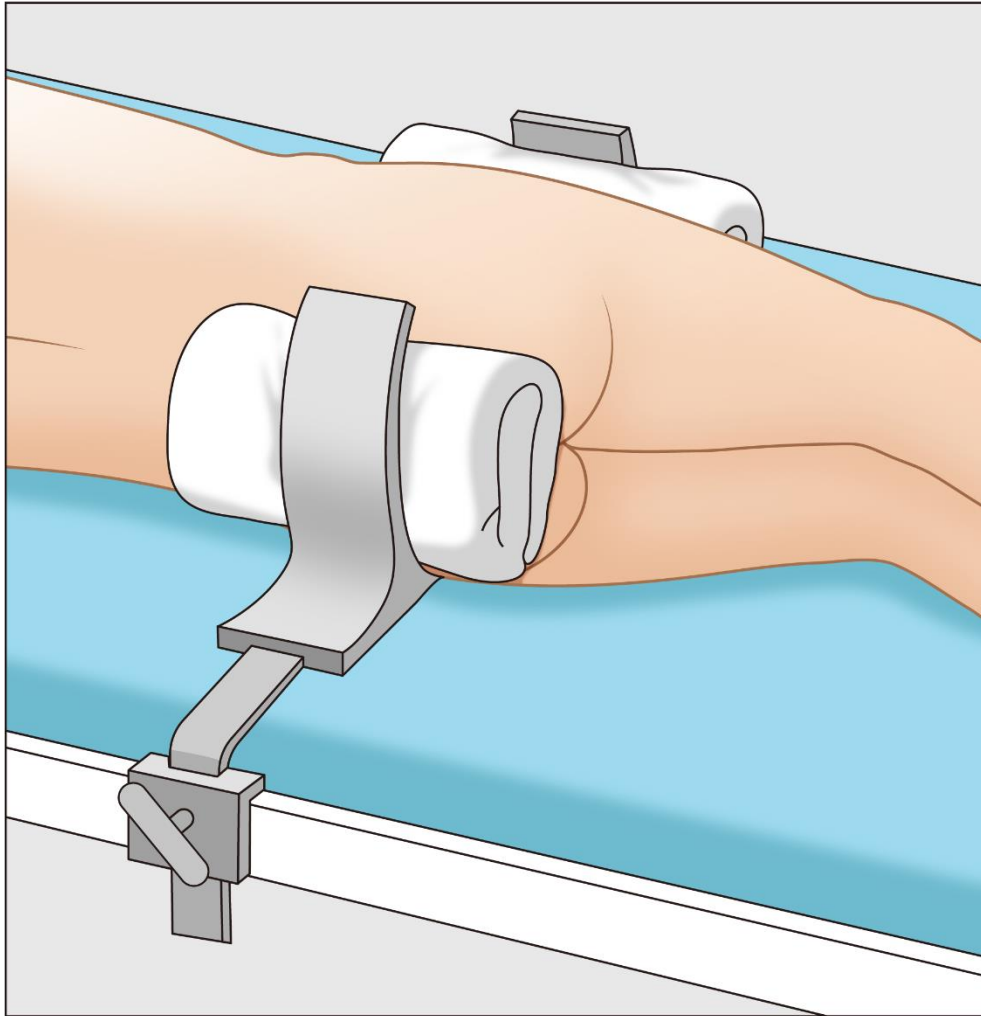


Ipsilateral pubic ramus fracture during total hip arthroplasty is not rare: Does it matter?

Young-Seung Ko¹ MD; Han Jin Lee² MD; Hong Seok Kim¹ MD, PhD; Jeong Joon Yoo¹ MD, PhD

Electronic Supplementary Material





Supplement Figure 1. The lateral hip positioner secured the pelvis of the patient in lateral decubitus position.

Correspondence to: Jeong Joon Yoo, MD, PhD

Department of Orthopaedic Surgery, Seoul National University College of Medicine, Seoul, South Korea

101, Daehak-ro, Jongno-gu, Seoul, Republic of Korea

TEL: +82-2-2072-1994

FAX: +82-2-764-2718

E-mail: jjyos@snu.ac.kr