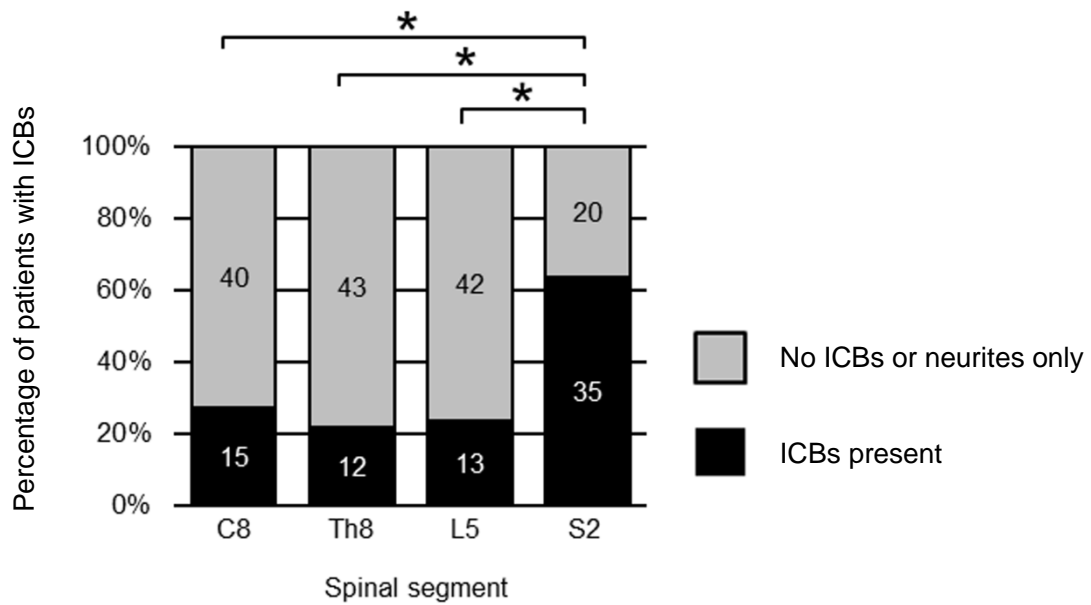


## Additional file 2: Figure S1

Frequency of intraneuronal cytoplasmic bodies (ICBs) in the large motor neurons at different levels of the ventral horn in symptomatic subjects



Symptomatic subjects (Parkinson's disease and dementia with Lewy bodies) (n = 55). \*P < 0.01. ICBs, intraneuronal cytoplasmic bodies.