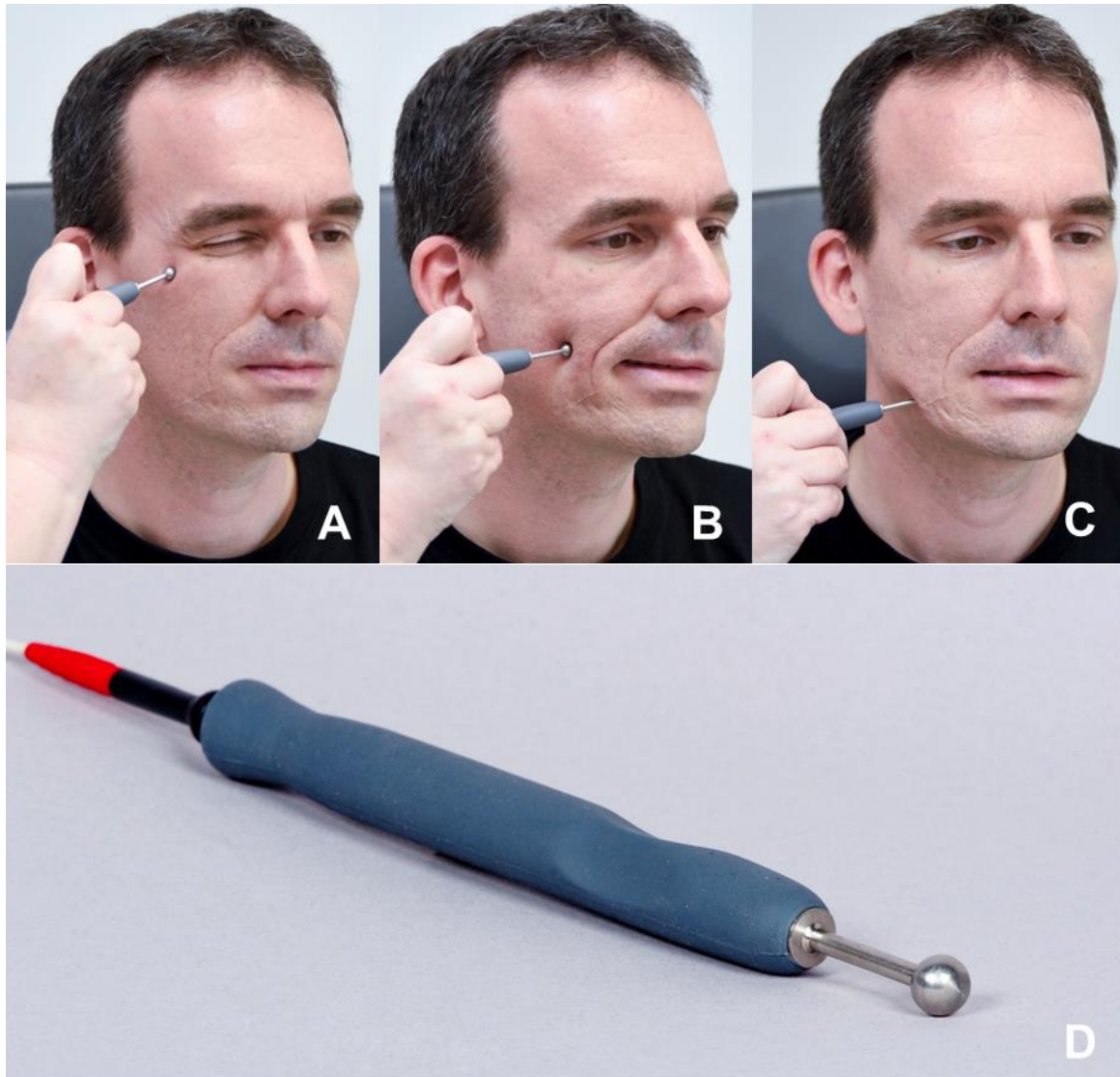


Supplement Figure 1

Guntinas-Lichius et al.

Facial nerve electrodiagnostics for patients with facial palsy - a clinical practice guideline



Supplement Figure 1. Facial nerve mapping (FNM). **A:** FNM of a zygomatic branch innervating the orbicularis oculi muscle; **B:** of a buccalis branch innervating the zygomaticus muscle; **C:** of a marginalis branch innervating the depressor anguli oris. **D:** Example of a ball electrode used as stimulator during FNM.