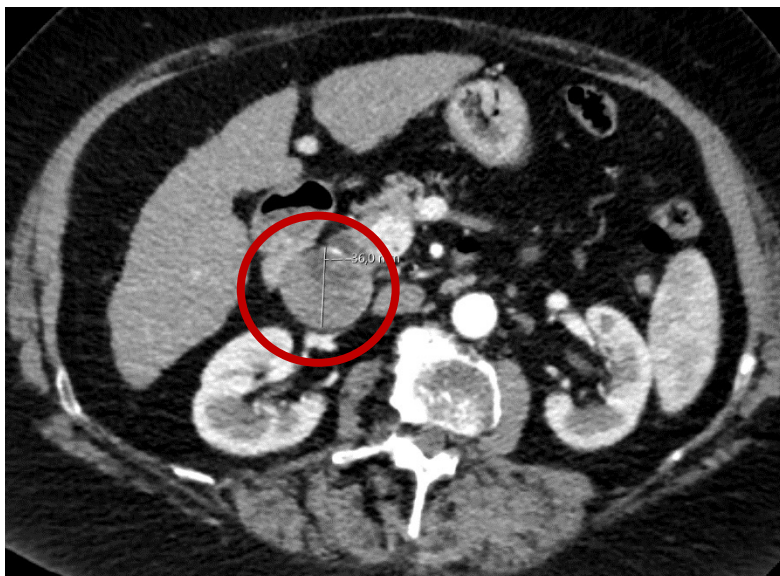


**Supplementary Figure S3:**

Patient example for early tumor shrinkage.

In this patient who had undergone tumor ablation previously one abdominal lymph node metastasis (TL 1) was detected in follow-up with a diameter of 36 mm. After initiation of systemic treatment with immunotherapy (nivolumab), the lymph node metastasis shrank to 14 mm (ETS 61.1%, PR).

Baseline



Follow-up

