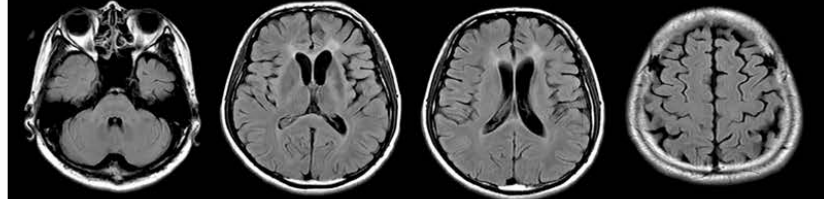
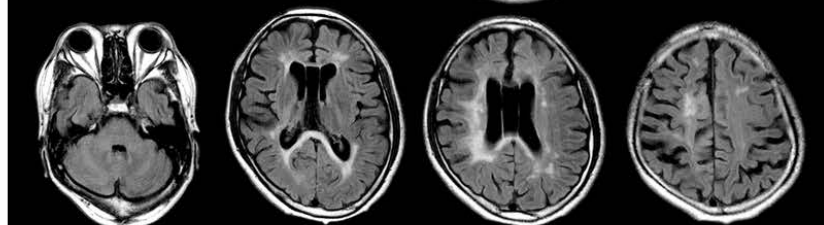


## Supplementary Figure 1: MRI images of patients with *CSF1R* variants

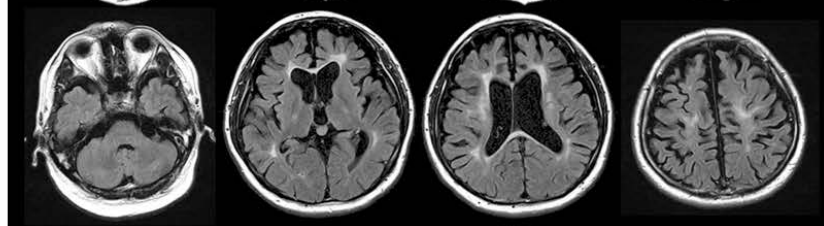
Patient 2:  
p.His362Arg,  
(Homozygote)  
29 years old, male  
4 years after onset



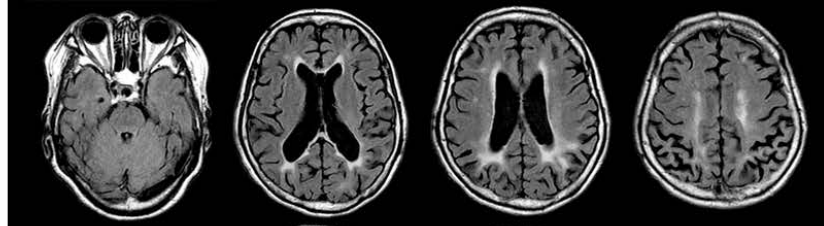
Patient 3:  
p.Ile662Thr  
46 years old, male  
6 years after onset



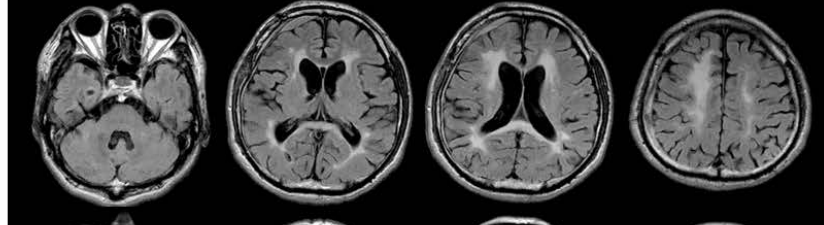
Patient 4:  
p.Gly765Asp  
47 years old, male  
3 years after onset



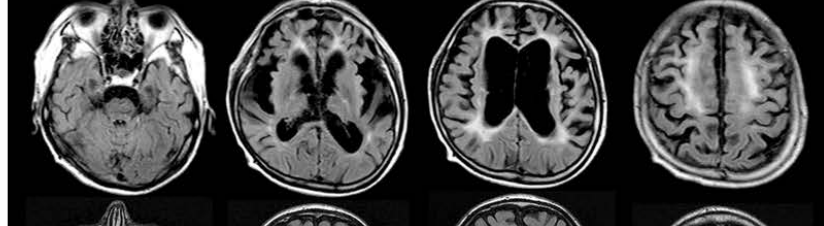
Patient 5:  
p.Asp778Glu  
66 years old, female  
6 years after onset



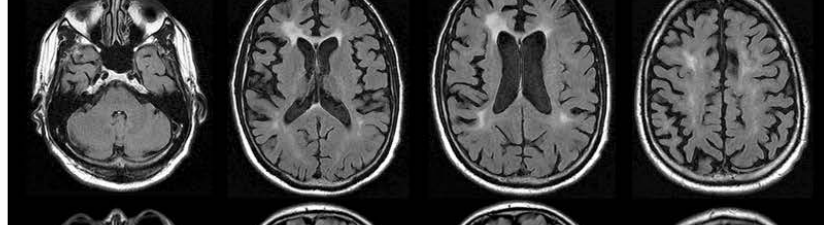
Patient 6:  
p.Ile794Phe  
57 years old, male  
1 year after onset



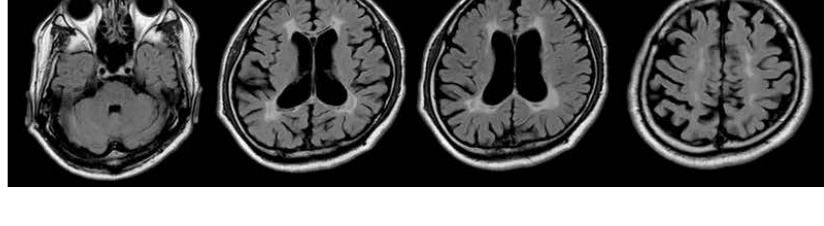
Patient 9:  
p.Pro878Ser  
55 years old, male  
6 years after onset



Patient 10:  
p.Pro878Ala  
62 years old, male  
5 years after onset



Patient 11:  
p.Tyr886GlnfsTer55  
46 years old, male  
1 year after onset



**Supplementary Figure 2: CT scans of patients with *CSF1R* variants**

Patient 2:  
p.His362Arg  
(Homozygote)  
29 years old, male  
4 years after onset

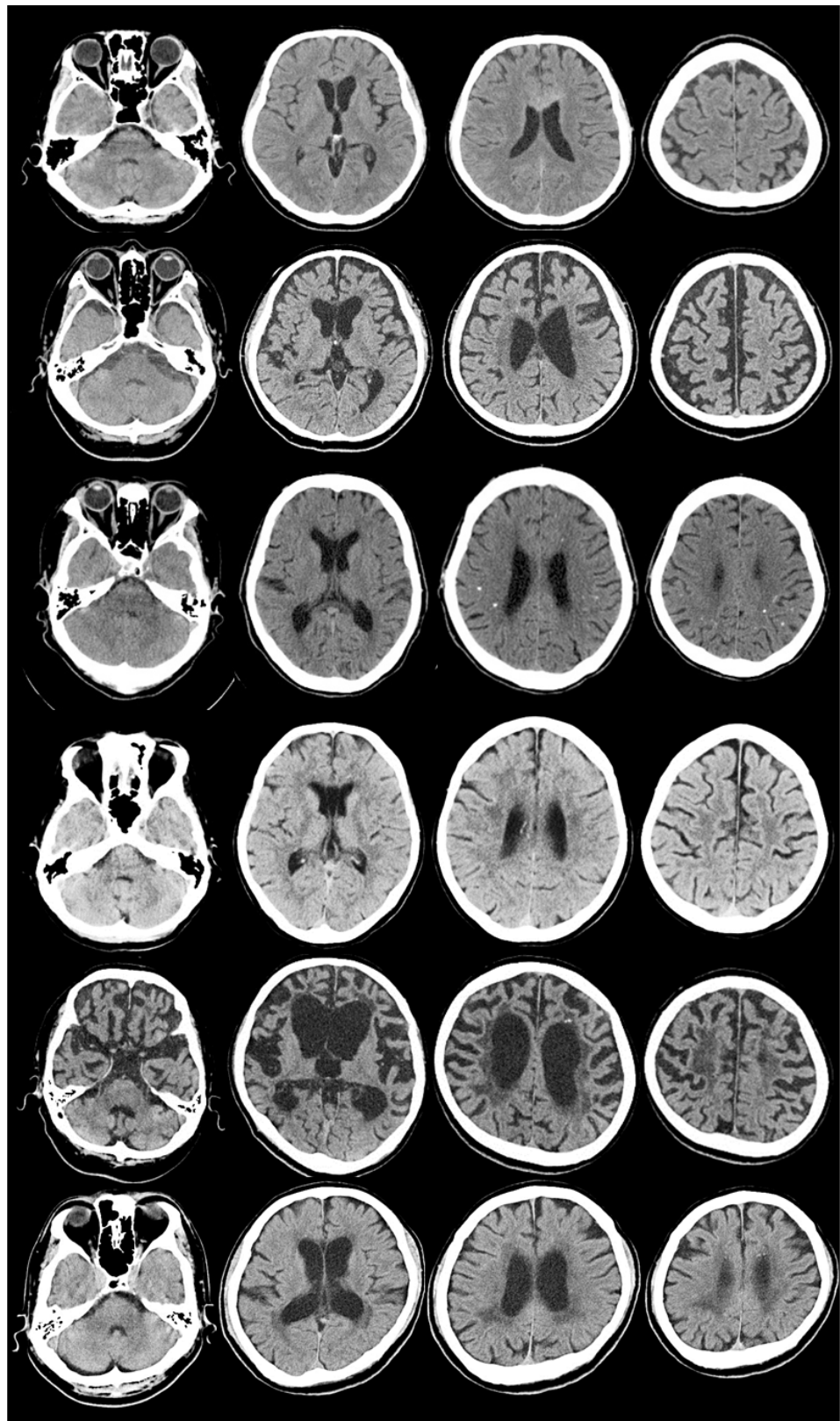
Patient 4:  
p.Gly765Asp  
47 years old, male  
3 years after onset

Patient 5:  
p.Asp778Glu  
66 years old, female  
6 years after onset

Patient 7:  
p.Ile794Thr  
35 years old, female  
2 years after onset

Patient 9:  
p.Pro878Ser  
55 years old, male  
6 years after onset

Patient 11:  
p.Tyr886GlnfsTer55  
46 years old, male  
1 year after onset



**Legend:**

Calcification was present in *patient 4, 5, 7, 9, and 11*. *Patient 2* did not show calcification by CT with thin slice.